



THE OPTHALMIC PERCUTANEOUS TRANSLUMINAL
CATHETER (OPTIC) SYSTEM

*For the treatment of
Age-Related Macular Degeneration (AMD)*

OCUDYNE – OCULAR REPERFUSION

Cardiovascular Disease and AMD

*Virtually every confounding
principle of AMD is explained
by ocular perfusion*

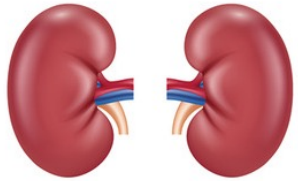
Comprehensive Preclinical Research

*10 years of research, imaging,
cadaver studies, non-invasive
and minimally invasive human
studies*

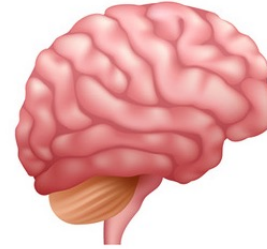11 Patients Treated

*Positive Safety Profile
Improvements In:
BCVA
Reading Speed
Quality of Life
Blood flow
Choroidal Thickness
GA Progression*

COMPROMISED PERFUSION

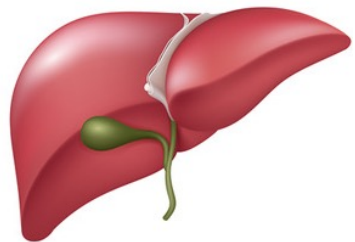


Acute Kidney Injury
Activation RAAS
Atrophy
Ischemia

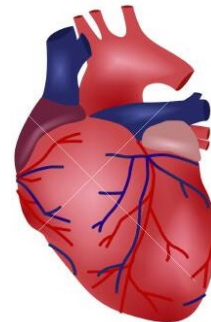


Cognitive impairment
Increased TIA
Increased aneurysm
Ischemia

Ischemia → Hypoxia

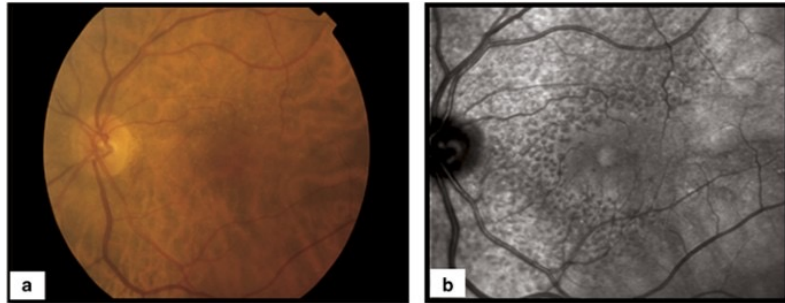


- Fibrosis
- Impaired Bile and Detox
- Necrosis
- ***Ischemia***

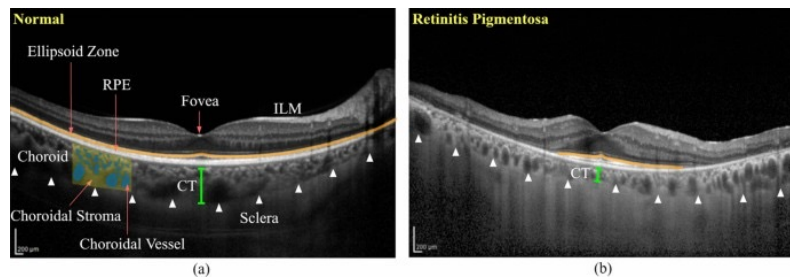


Heart disease
Cardiac hypertrophy
Hypertension
Bradycardia
Ischemia

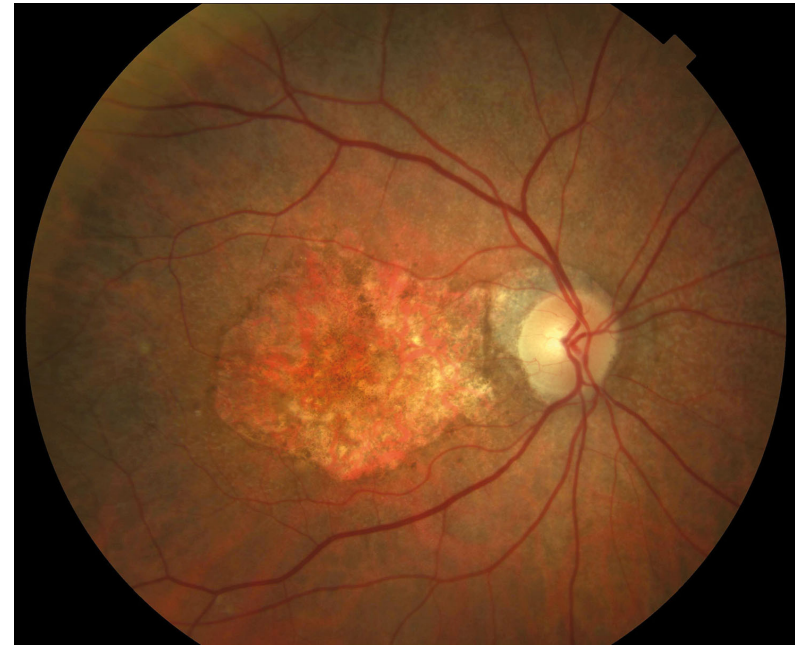WHAT WOULD WE SEE IF OCULAR PERFUSION IS AN ISSUE?



Reticular pseudodrusen



Thin Choroid



Geographic Atrophy

LARGE MARKET

AGE-RELATED MACULAR DEGENERATION (AMD)

- Leading cause of vision loss world wide
- More than cataracts and glaucoma combined
- Affects 11 million US, 25 million world wide

Normal Vision

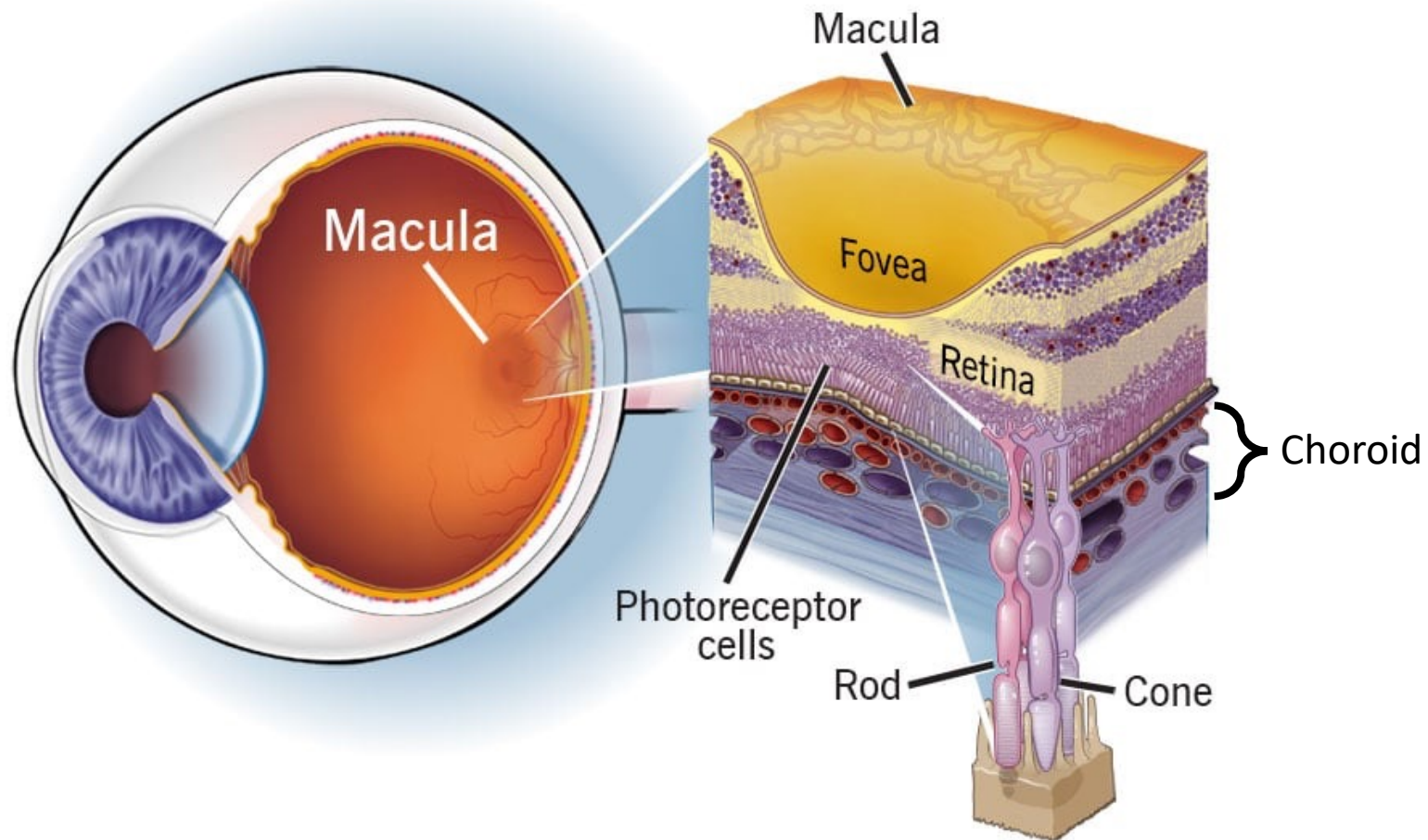


AMD Vision



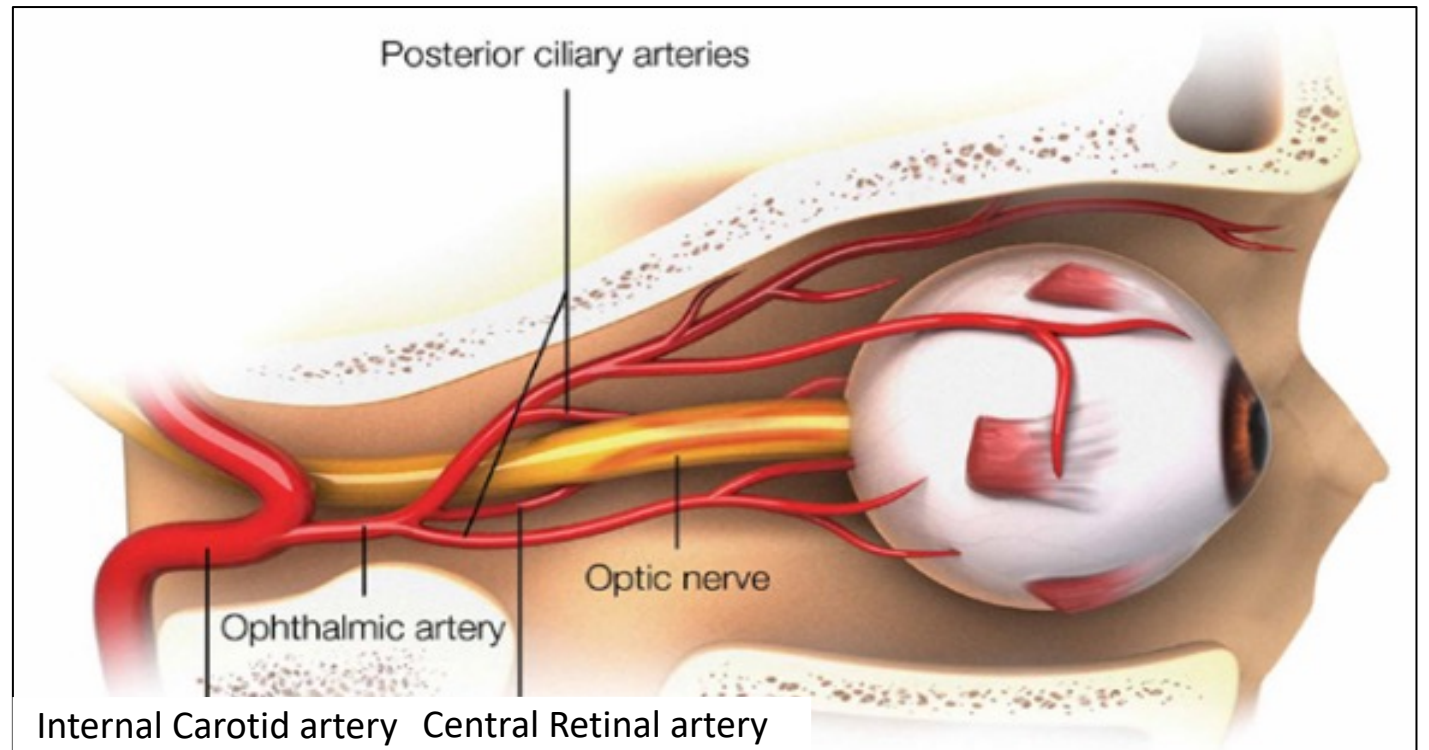
MACULAR ANATOMY

Macula: Anatomy, Function & Common Conditions

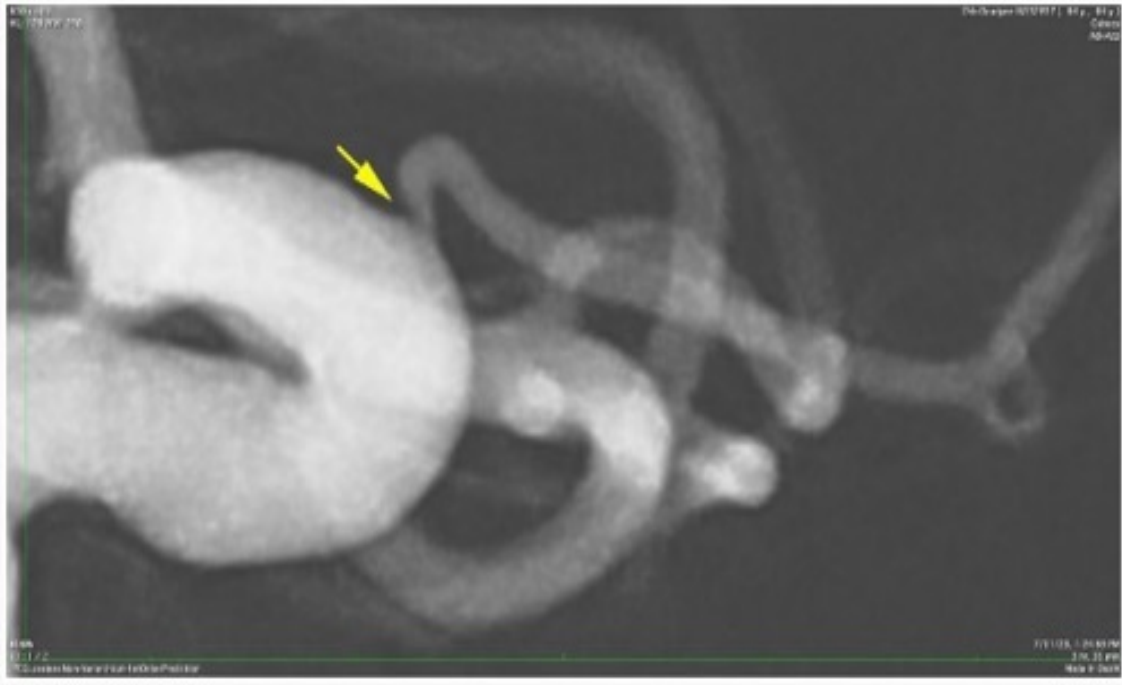


PERFUSION DEFICIT: MECHANISM OF ACTION

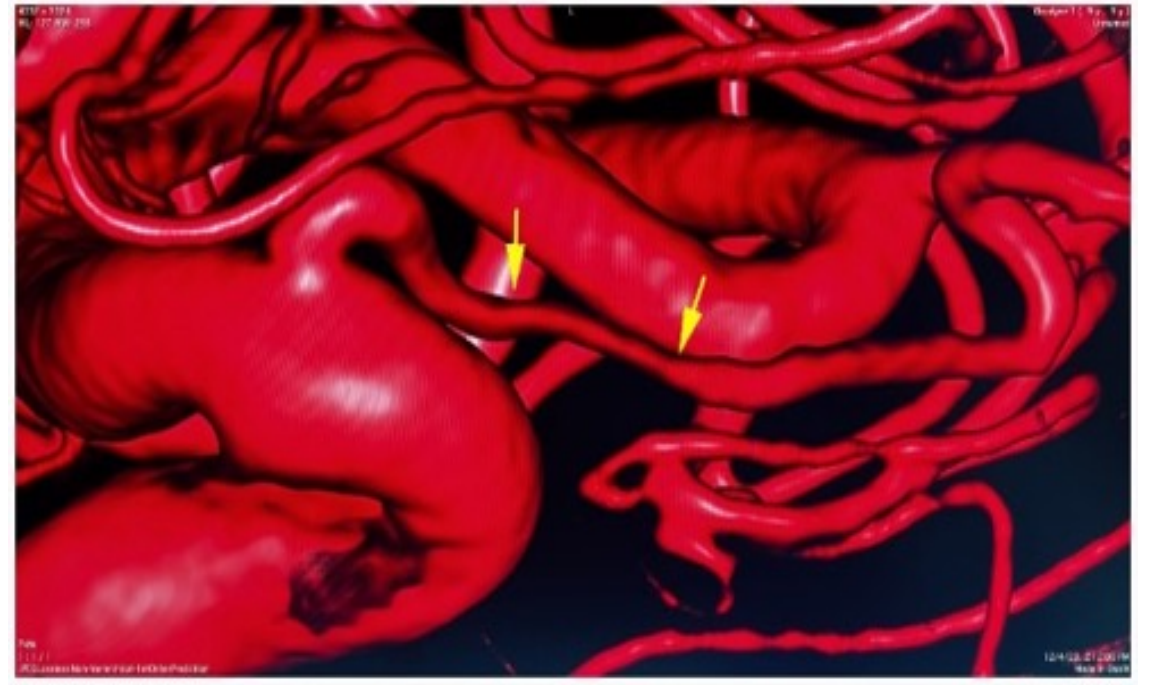
Compromised blood flow to the back of the eye is a significant contributing factor to AMD (wet and dry). Improving blood flow with interventional devices will disrupt the disease process, and halt progression.



PERFUSION DEFICIT: MECHANISM OF ACTION



Focal OA ostium stenosis – 2D DSA



Diffuse OA stenosis - 3D DSA

PERFUSION DEFICIT: MECHANISM OF ACTION

Healthy eye



Reduction in

choroidal perfusion
drives **chronic ischemia**

+

Influence of:

- Genetics
- Environment
- Aging



Ischemia

Drives hypoxia in RPE: **Initiates** the following conditions (examples):

- Mitochondrial metabol (dysf fission/fusion)
 - Increased: Oxidative stress
 - reduced nitric oxide synthase – (NOS)
 - reactive oxygen Species (ROS) damages DNA, lipids, proteins & dysregulates autophagy)
 - Increased: Glutamate induced cytotox
 - Decreased: ATP production
 - Decreased: Extracell matrix remodeling (BM)
 - Decreased: Amino acid (proline metabolism)
 - Decreased: Glucose transmission
- Increased: Connexin hemichannel openings
- Decreased: Apoptosis (increase in pyroptosis)
- Decreased: Pigment
- Decreased: Diffusion
- Decreased: Waste removal

**These processes
continue throughout all
disease stages**

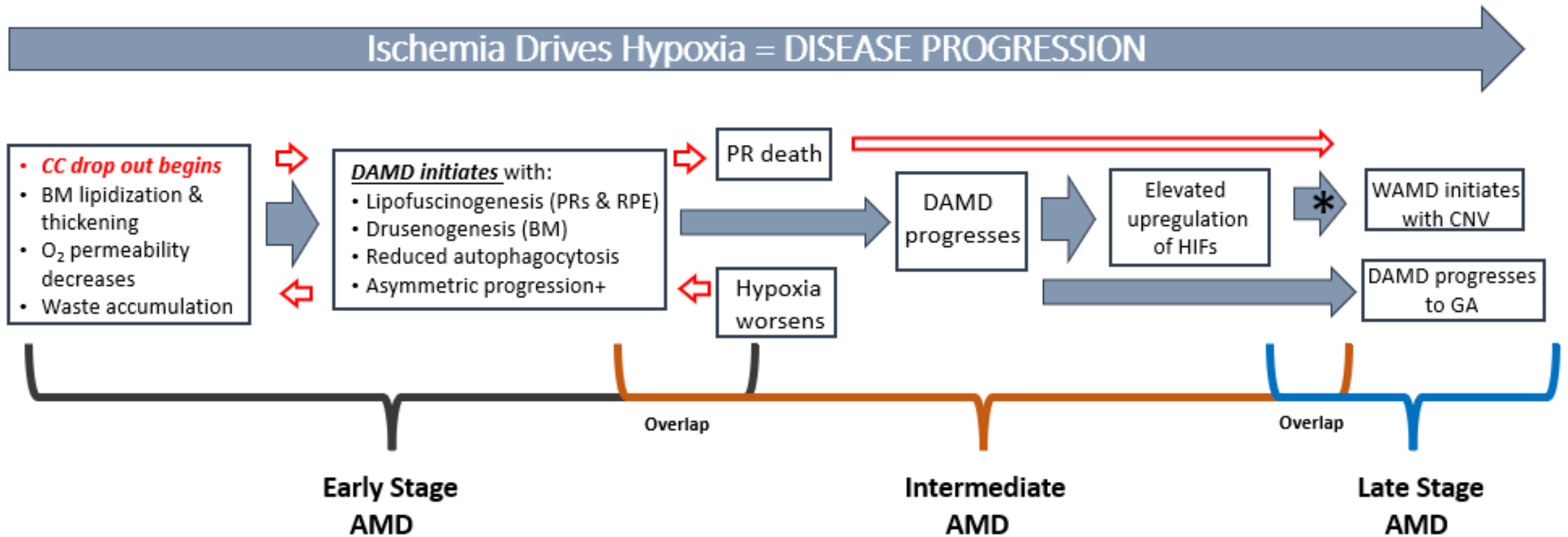


Hypoxia

Initiates inflammation, dysfunction & disease progression in RPE

- Affects sensory fibers:
 - Sympathetic/Parasympathetic
 - Trigeminal
- Upregulates:
 - Erythropoietin (EPO)
 - Angiopoietin 2 (ANG 2)
 - HIF 1 α ,2 α ,3 α
 - VEGF expression
- Initiates:
 - Dysf complement activation (upregulation of C3*/C5** primarily via alternative pathway)
 - Inflammation

PERFUSION DEFICIT: MECHANISM OF ACTION



Chronic Ischemic AMD

* Ischemia is the likely mechanism for progression of Dry AMD to Wet AMD

+ This disease flow also addresses common asymmetry

RELEVANT PUBLICATIONS

- *Journal of Ophthalmology (Mar 2020)*
Krytkowska, et al. Impact of Carotid Endarterectomy Choroidal Thickness and Volume in Enhanced Depth Optical Coherence Tomography Imaging
- *American Journal of Neuroradiology (July 2021)*
Hibert, et al. Altered Blood Flow in the OA and ICA in Patients with AMD Measured Using Noncontrast MRA at 7T
- *American Journal of Ophthalmology (Sept 2021)*
Rosenfeld, et al. An update on the Hemodynamic Model of AMD
- *Journal of Neuro Interventional Surgery (Jan 2022)*
Lylyk, et al. OA Angioplasty for Age-Related Macular Degeneration
- *RETINA (July 2022)*
Thomson, et al. Subretinal Drusenoid Deposits and Soft Drusen – Are They Markers for Distinct Retinal Diseases?
- *Investigative Ophthalmology & Visual Science (April 2023)*
Li, et al. Decreased Macular Choriocapillaris Perfusion in Eyes With Macular Reticular Pseudodrusen Imaged With Swept-Source OCT-A
- *Asia Pacific Journal of Ophthalmology (Jan 2024)*
Smith et al. Subretinal Drusenoid Deposits, AMD and Cardiovascular Disease

RELEVANT ACCOMPLISHMENTS

➤ Cadaver Study

- Objective: Evaluate ICA / OA complex anatomy and conduct histology
- Data on File

➤ 7T MRI Study

- Objective: Non-invasive MRI evaluation of ICA / OA hemodynamics
- Published AJNR Jan 2021

➤ Compassionate Use Project

- Objective: Feasibility of using commercially available products to conduct OA
- Published JNIS Jan 2022

➤ OUS Safety & Feasibility Study

- Objective: Safety and feasibility of the OPTiC System for the treatment of dry AMD

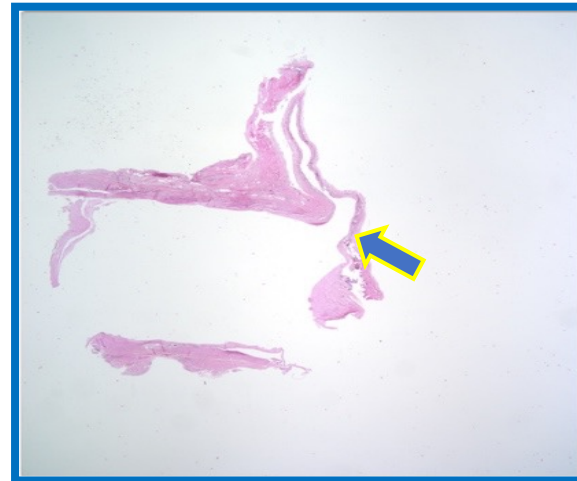
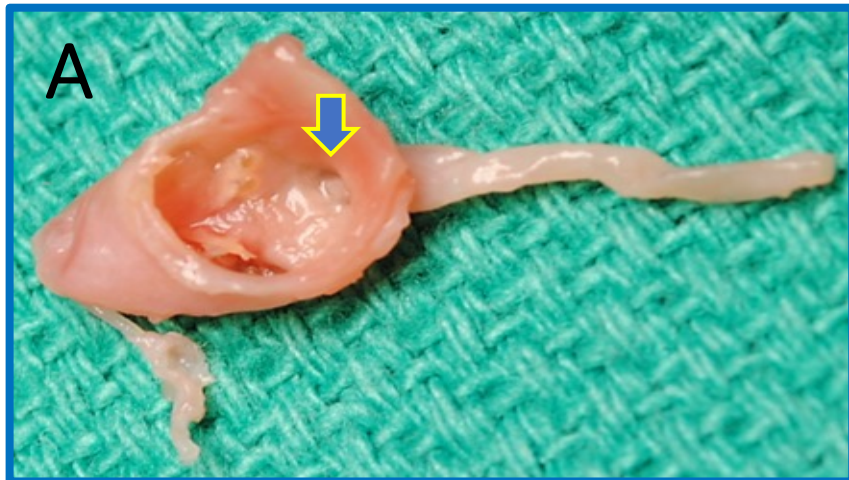
- Three posters providing OcuDyne OUS data were presented at ARVO 2024 (Seattle, WA USA – May 2024)
 - A poster has been presentation at Club Jules Gonin 2024 (Palma de Mallorca – May 2024)

CADAVER STUDY – SUMMARY

➤ Cadaver Study

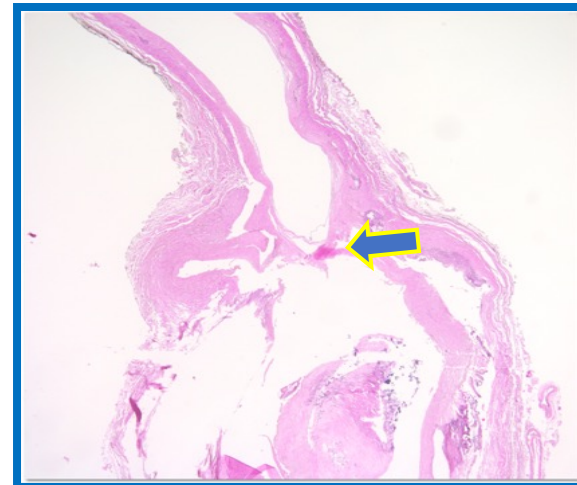
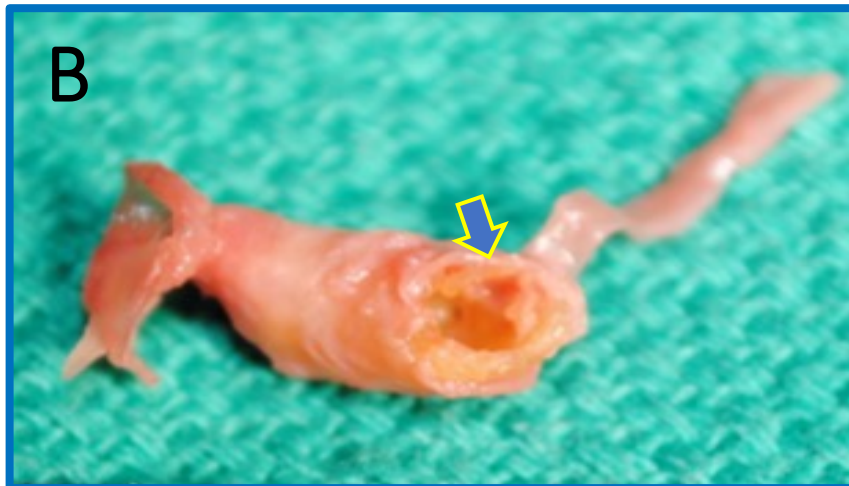
- Objective: Evaluate ICA / OA complex anatomy and conduct histology
- 42 eyes with reported AMD Dx; 17 Control
- Mean (SD) age: 81.9 (10.1)
- Histology demonstrated medial calcification in OA
- Data on File

CADAVER STUDY – HISTOLOGY



Panel A

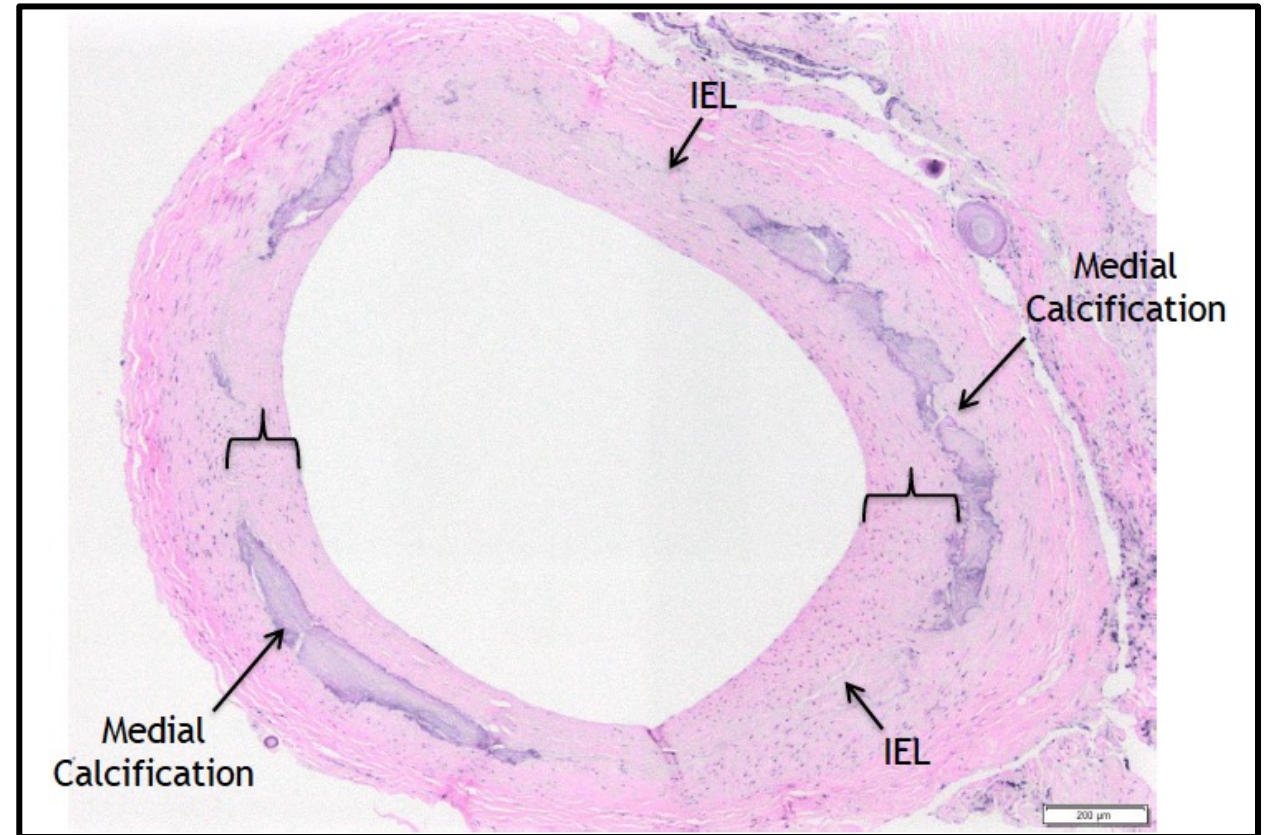
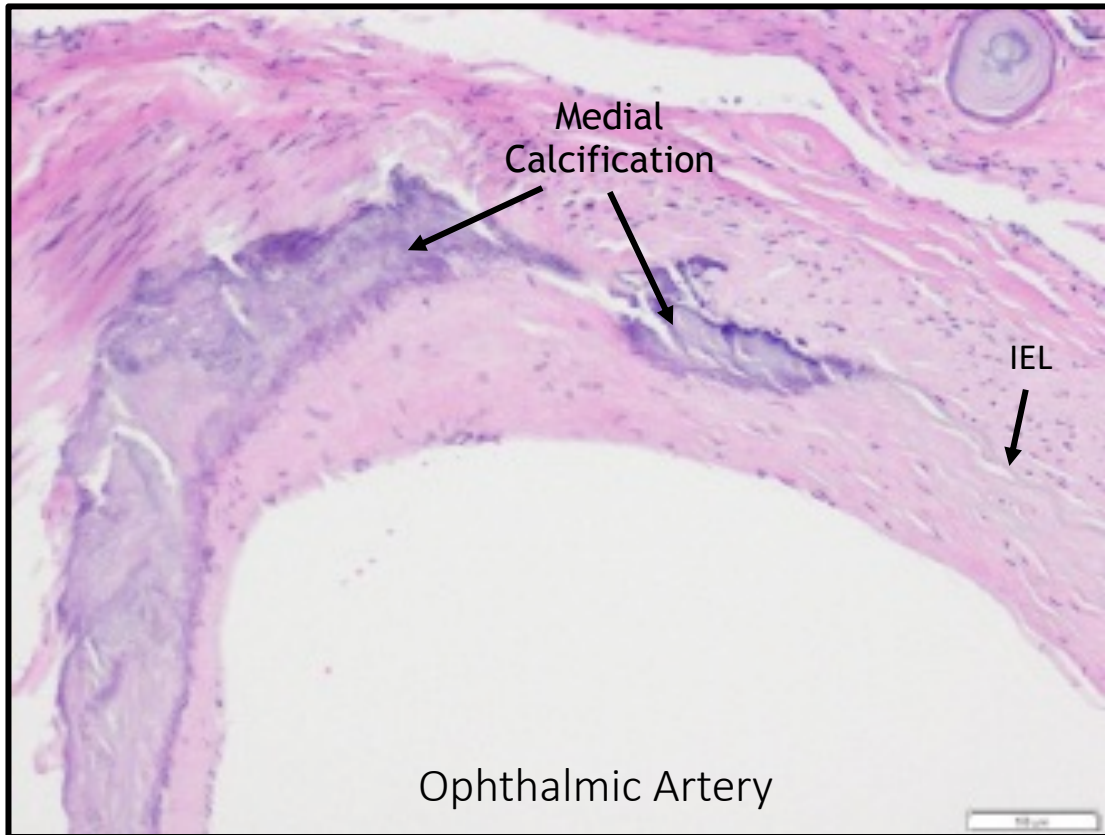
Control: no lesion(s) evident



Panel B

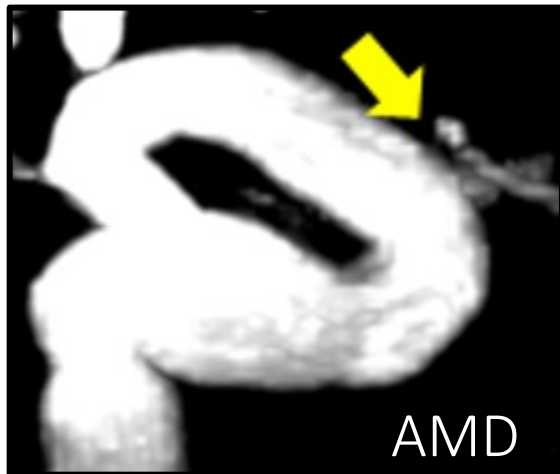
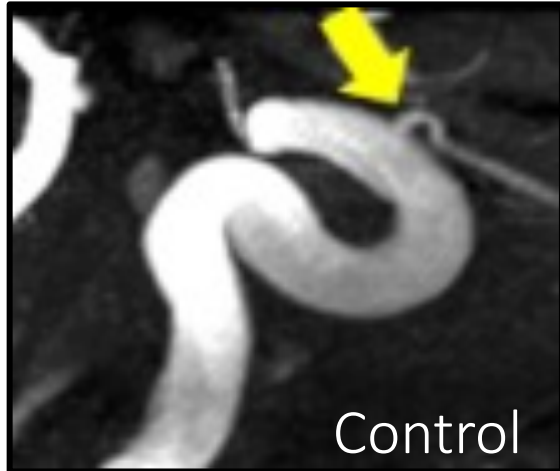
Lesion at the OA ostium demonstrating near total occlusion and apparent intramural calcifications in the short limb

CADAVER HISTOLOGY – INTRA ARTERIAL LESIONS



IEL = internal elastic lamina

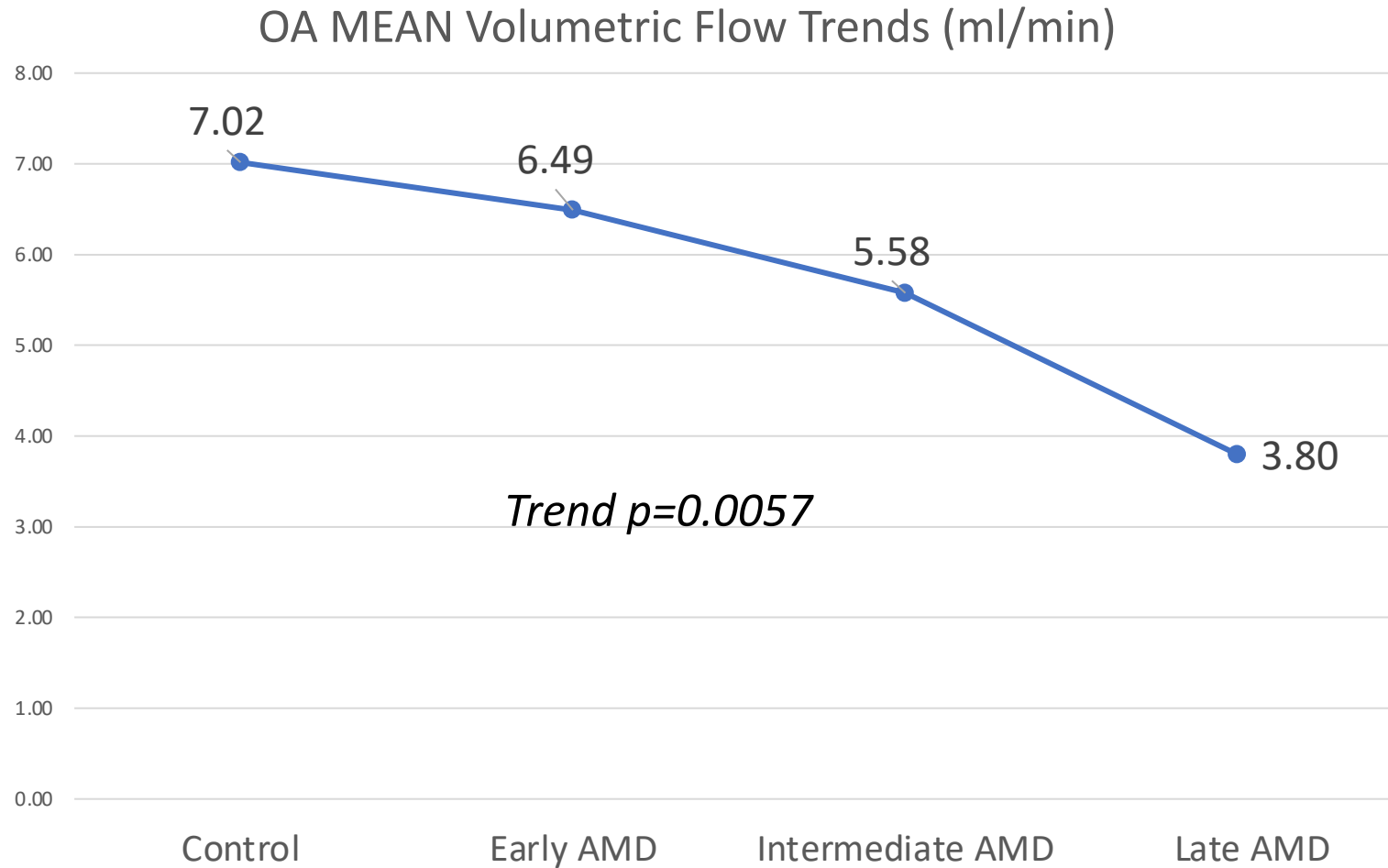
7T-MRI STUDY – SUMMARY



➤ 7T-MRI Study

- Objective: Non-invasive MRI evaluation of ICA / OA hemodynamics
- 52 eyes with graded AMD Dx; 34 Control
- Developed custom coils & algorithms
- 300 μm resolution without contrast use
- Included flow rate statistical analysis
 - Linear / volumetric hemodynamics
 - Resistive index in ICA & OA
- Conducted at Martinos Center for Biomedical Imaging
- Published AJNR July 2021

7T-MRI STUDY – OA VOLUMETRIC FLOW



ENDARTERECTOMY – CONTEMPORARY DISCOVERIES

- Carotid endarterectomy in asymptomatic patients is reproducibly associated with improved retinal function in ipsilateral eye and early treatment may provide protection of neuroretinal function.¹
- Improved blood flow of the ophthalmic artery following carotid endarterectomy improves subjective and objective assessments of visual function, including visual acuity, kinetic and static visual fields, P2 latency, and ocular pressure amplitude.²
- Carotid endarterectomy is considered an effective method for improving ocular circulation.³

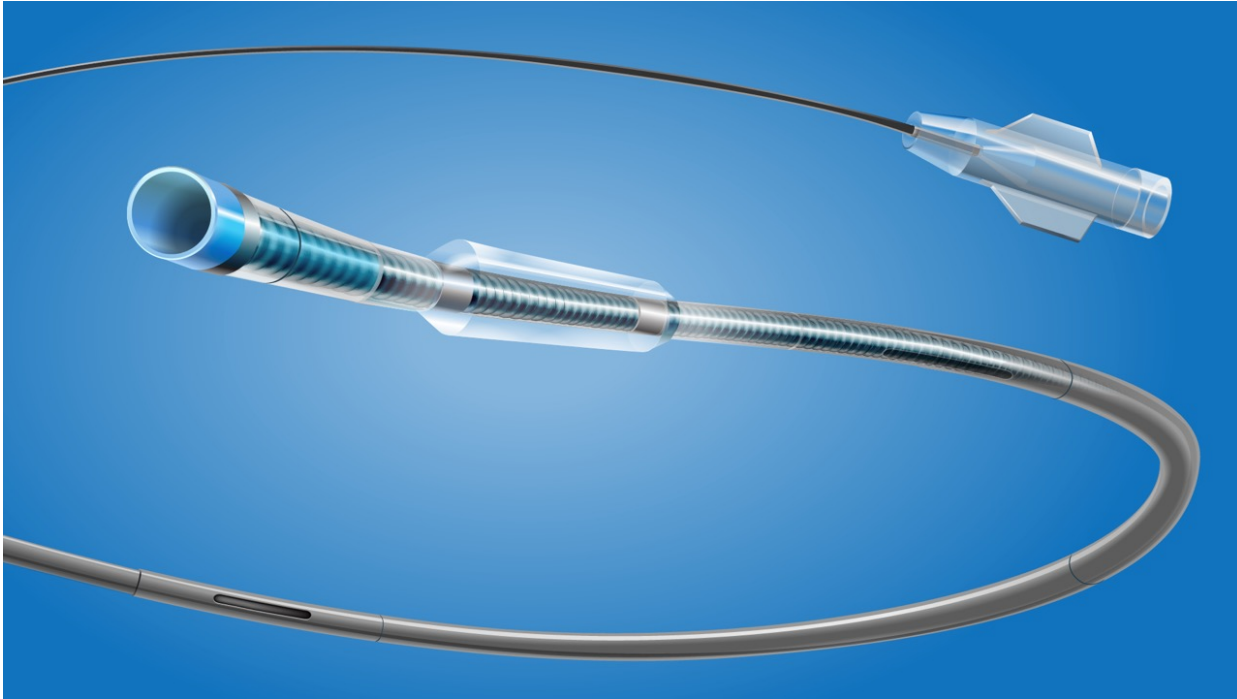
-
- **NO OTHER CURRENT OR PRIOR APPROACH ADDRESSES THE QUESTION OF ASYMMETRY IN DISEASE PROGRESSION**
 - **UTILIZING A MORE DIRECT MEANS TO PROVIDE COMPLEMENT INHIBITION**

1. Machalinska, et al. *Effect of carotid endarterectomy on retinal function in asymptomatic patients with hemodynamically significant carotid artery stenosis. Polish Archives of Internal Medicine.* 2017; 127 (11)
2. Yan, et al. *Visual Outcome of Carotid Endarterectomy in Patients with Carotid Artery Stenosis. Annals of Vascular Surgery.* 2019; 58: 347-356
3. Krytkowska, et al. *Impact of Carotid Endarterectomy on Choroidal Thickness Volume in Enhanced Depth Optical Coherence Tomography Imaging. Jour of Ophthal.* Vol 2020. ID 8326207

OcuDYNE CLINICAL STUDY


OC-1901AR Argentina

OPHTHALMIC PERCUTANEOUS TRANSLUMINAL CATHETER (OPTIC) SYSTEM



Micro Balloon Catheter (MBC)

Illustrative Representation
Made Specifically for Ocular Anatomy



Aiming Micro Catheter (AMC)

OUS SAFETY & FEASIBILITY – STUDY DESIGN

PRIMARY OBJECTIVE: Evaluate the Safety and Feasibility of the OcuDyne OPTiC System in Subjects with Age-Related Macular Degeneration.

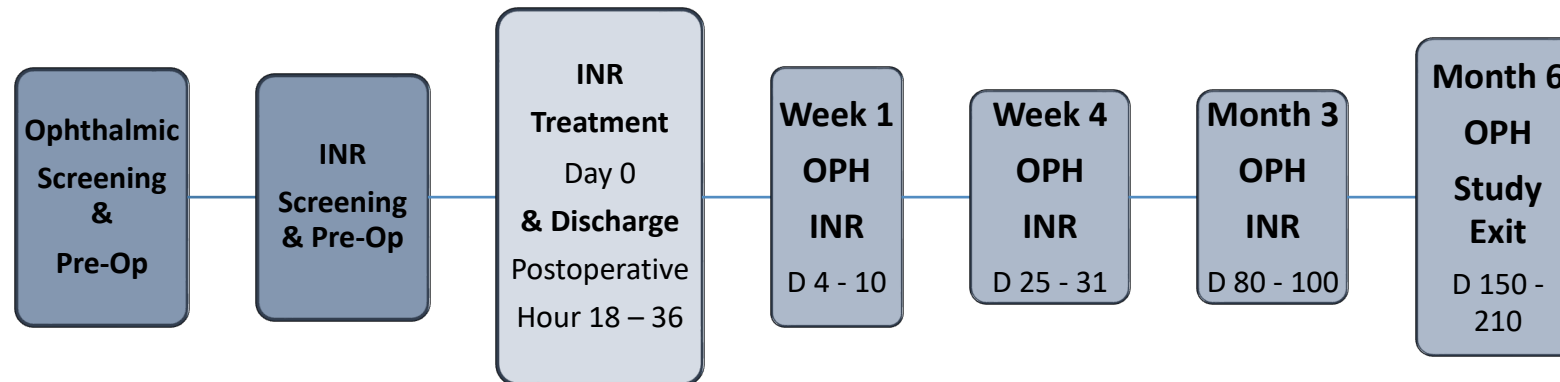
PRIMARY ENDPOINT: Procedure related complications – Intraoperative through INR Wk 4

SECONDARY ENDPOINTS:

- All associated with Safety / Feasibility
 - Incidence of AE
 - Procedural success
 - Surgeon experience

EXPLORATORY ENDPOINTS:

- All associated with Potential Efficacy Signals
 - Visual Acuities
 - Imaging
 - Functional Questionnaire



SAFETY AND FEASIBILITY – ARGENTINA TEAM



Endovascular Neurosurgery &
Interventional Radiology Team



Mario Saravia, MD PhD

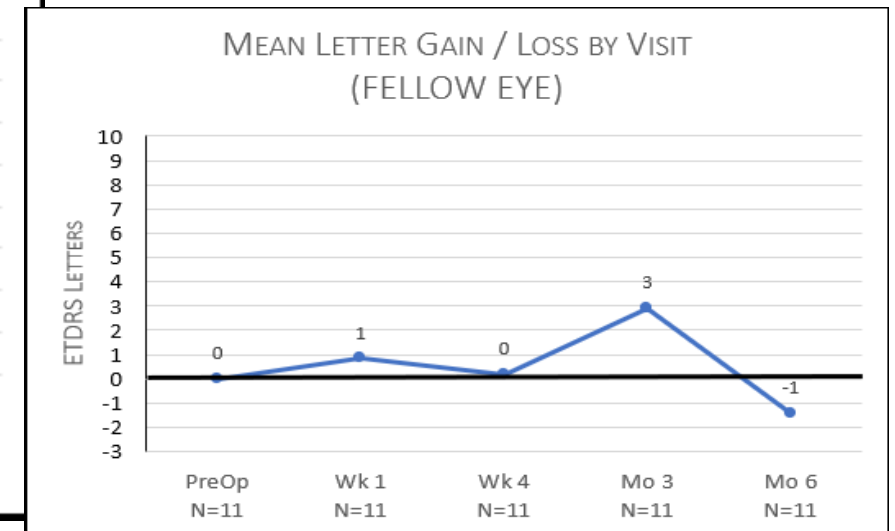
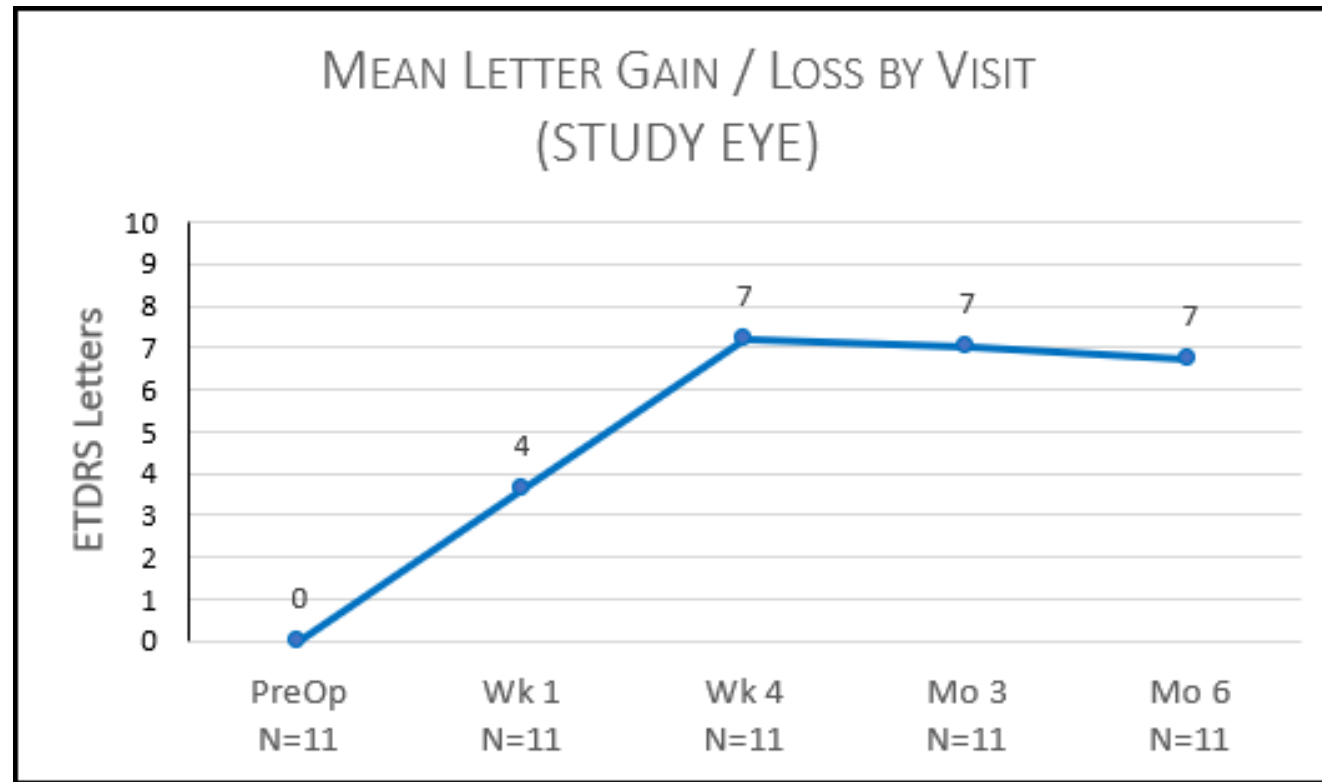


Ophthalmic Vitreoretinal Specialist
and Research Team

GLOBALY RESPECTED SURGEONS, INNOVATORS, AND KOLS

MEAN BCVA ETDRS LETTER CHANGE FROM BASELINE BY VISIT

CONSISTENT COHORT (N=11) THROUGH MONTH 6 VISIT

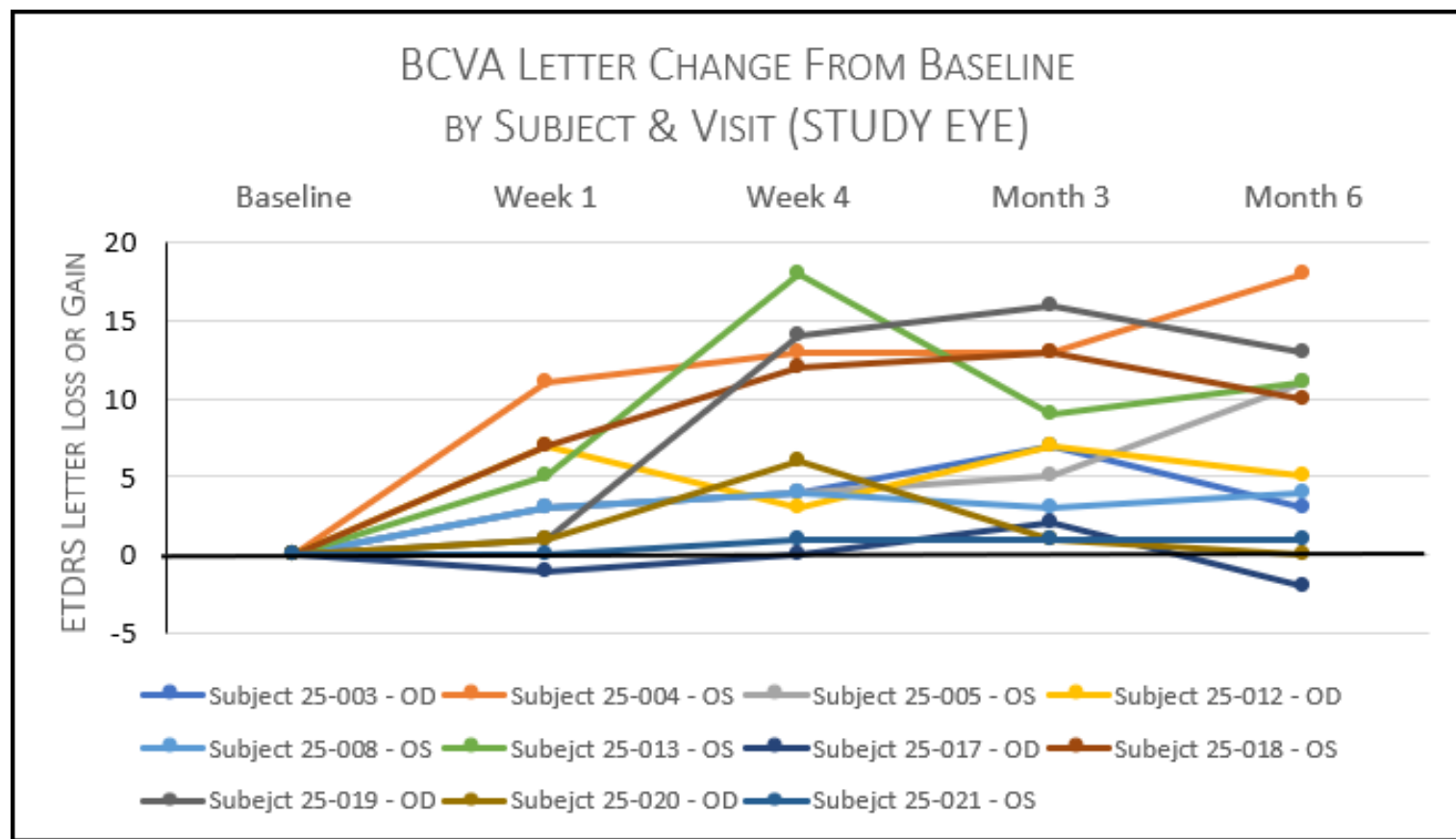


ETDRS LETTER GAIN / LOSS BY VISIT & SUBJECT (STUDY EYE)

ALL TREATED EYES THROUGH LAST AVAILABLE VISIT

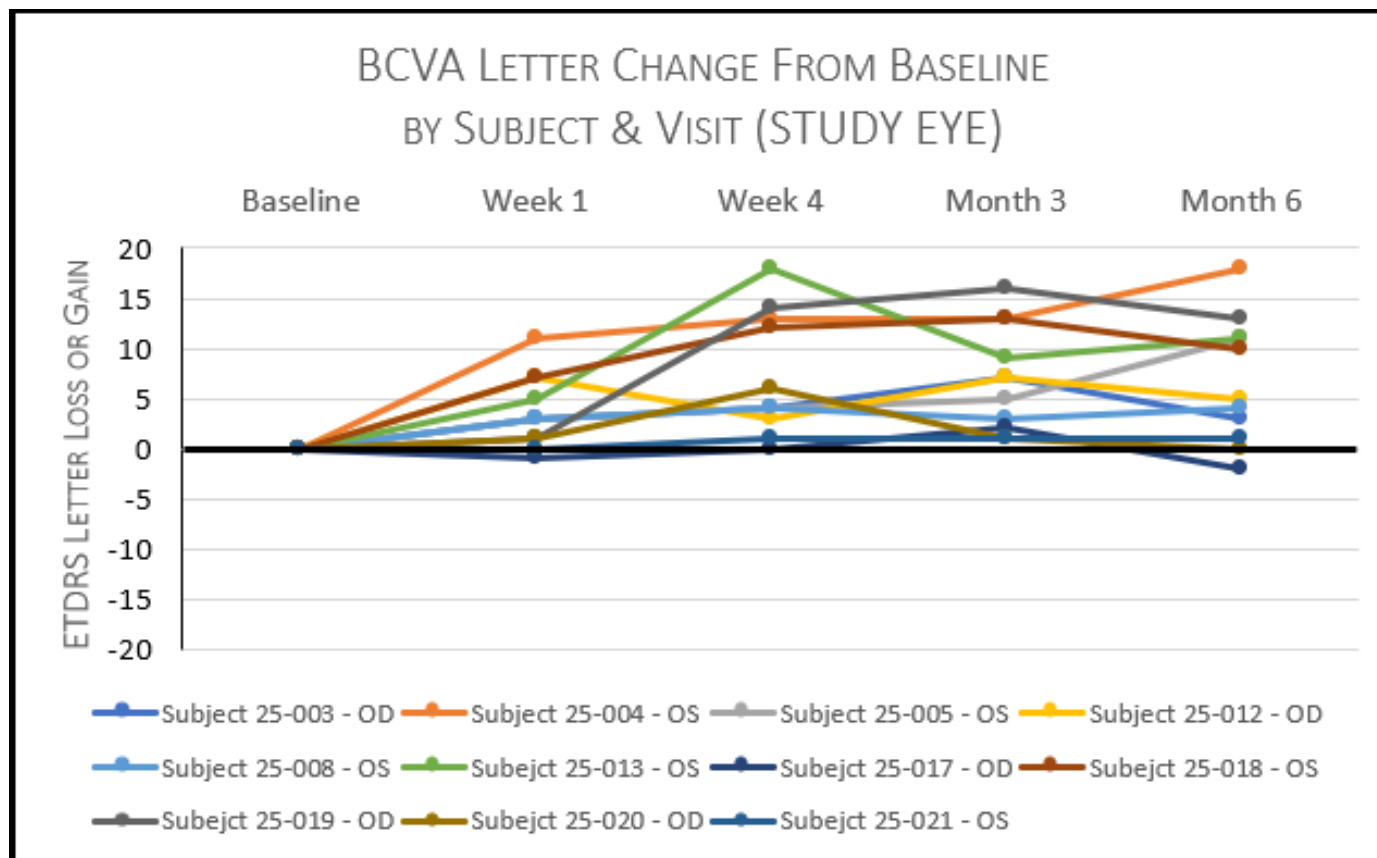
VISUAL ACUITY CHANGE AT
LAST AVAILABLE VISIT (N=11)

≥ 3 line gain:	1 (9.1)
≥ 2 line gain:	5 (45.4)
≥ 1 line gain:	6 (54.5)
< 1 line gain:	4 (36.4)
<hr/>	
< 1 line loss:	1 (9.1)
≥ 1 line loss:	0 (0.0)
≥ 2 line loss:	0 (0.0)



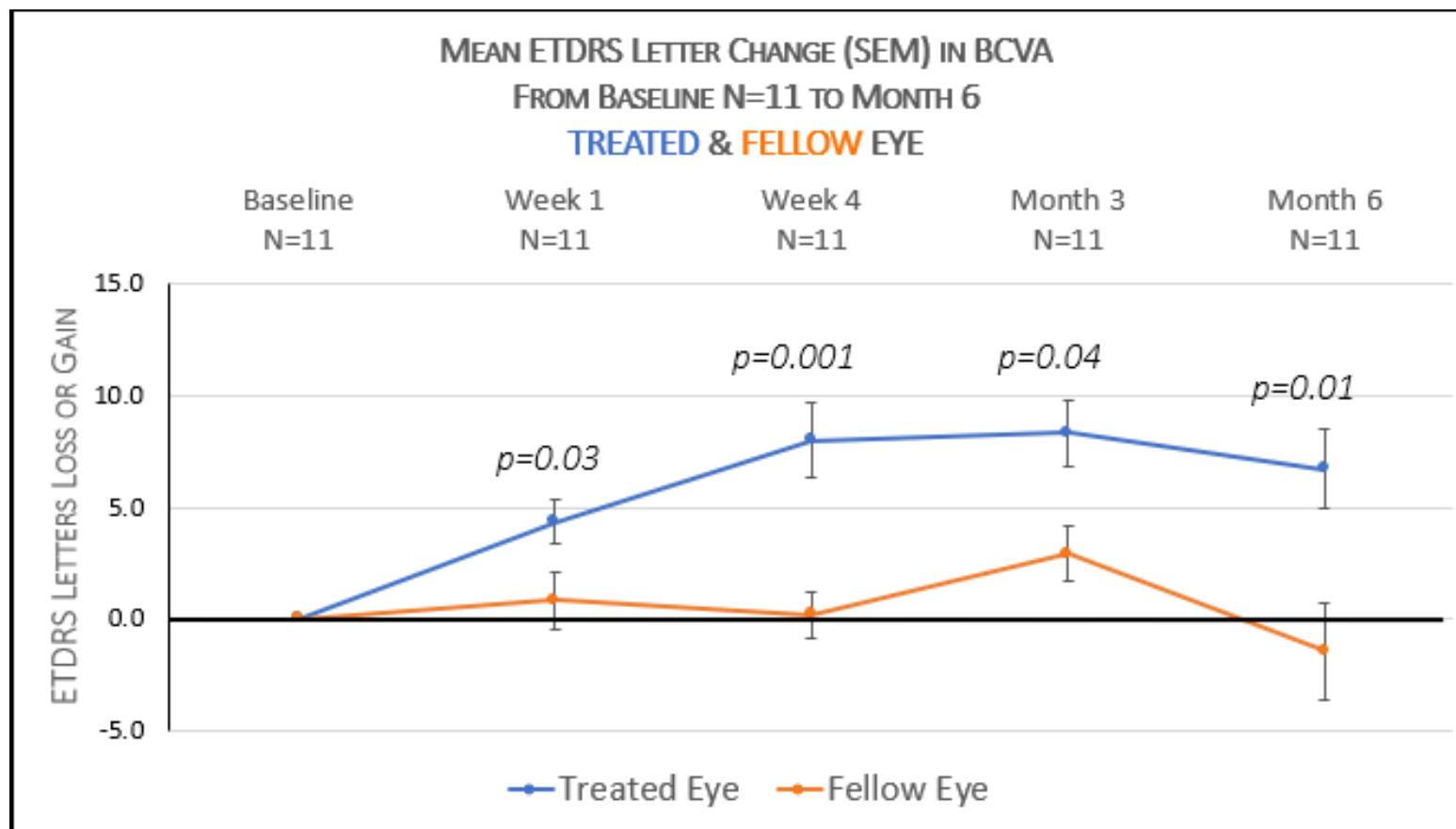
ETDRS LETTER GAIN / LOSS BY VISIT & SUBJECT

ALL TREATED COHORT THROUGH MONTH 6 EXIT VISIT



STUDY EYE VS. FELLOW EYE

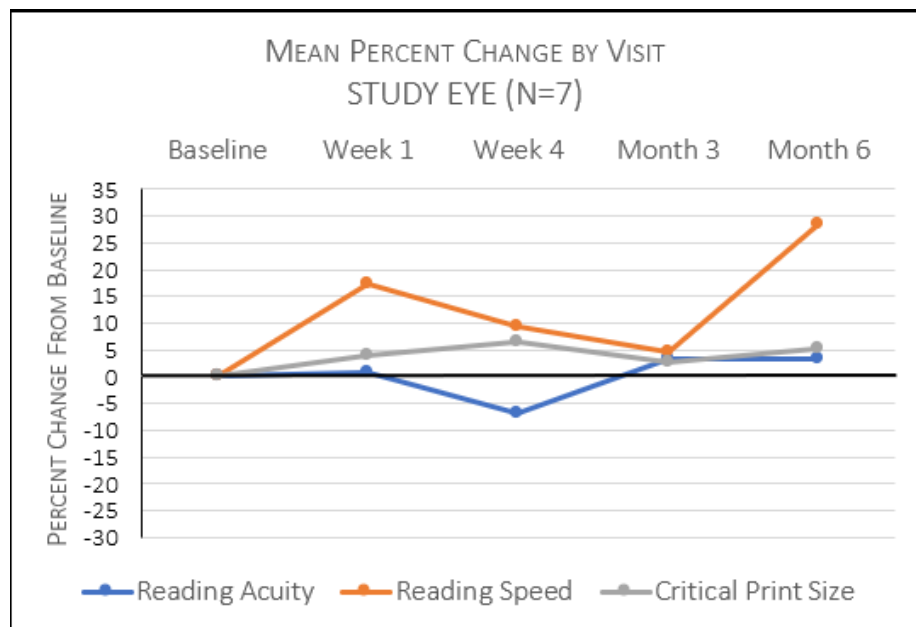
Mean ETDRS Change (SEM) BCVA



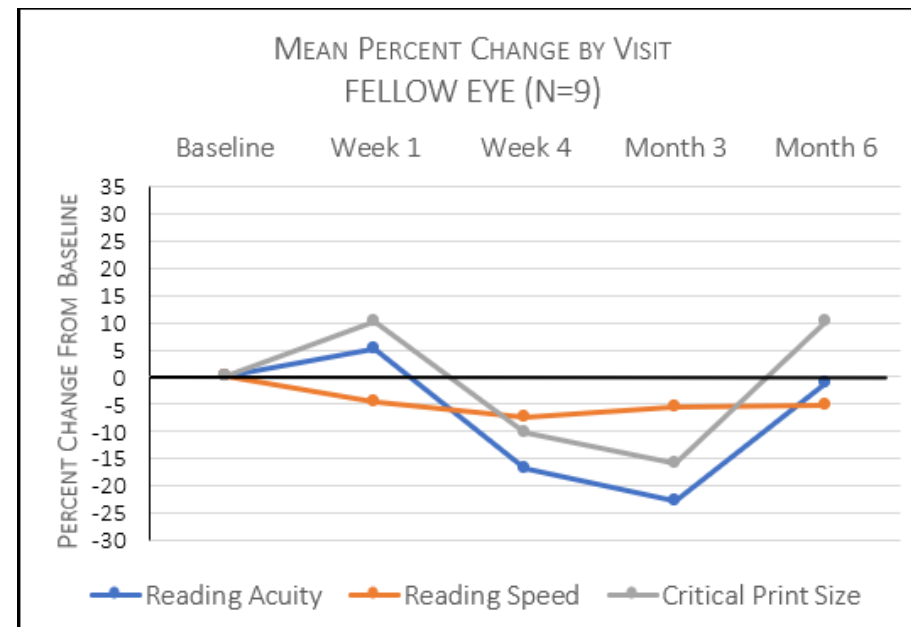
MN READING SCORES

Mean Percent Change From Baseline by Visit

First of its kind, demonstrated improvement



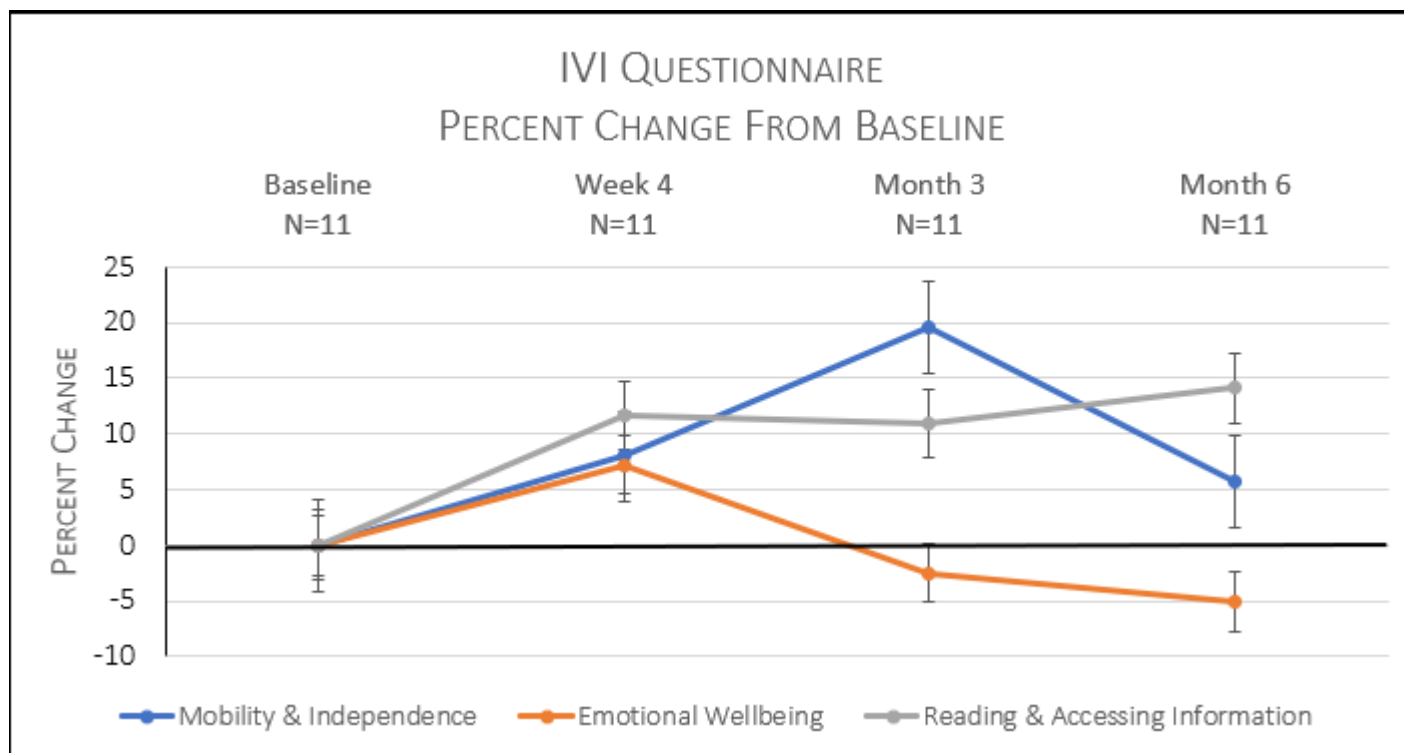
Improvement demonstrated in all measures. Smaller mean print size for both **Reading Acuity (3.4%)** and **Critical Print Size (5.1%)**, with the ability to read smaller print at an increased mean **Reading Speed of 28.5%**.



Increased mean **Critical Print Size (10.1%)** and a decrease in **Reading Speed (5.3%)** and **Acuity (1.2%)**. These data reflect Subjects reading smaller print at a slower speed with no meaningful change in Acuity.

IVI QUESTIONNAIRE – PERCENT CHANGE (SEM) FROM BASELINE

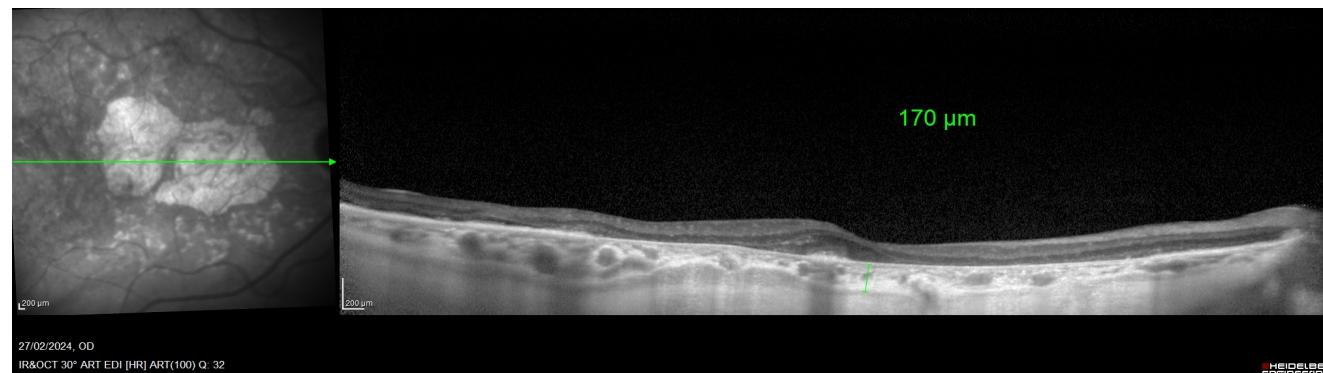
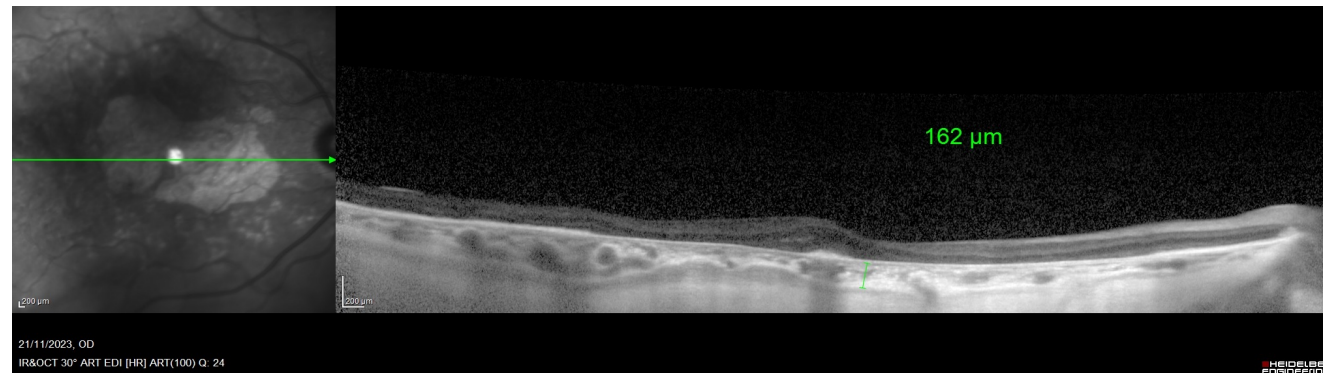
Consistent Cohort (N=11) to Month 6



Improvement over Baseline in both Mobility & Independence as well as Reading and Accessing Information. The former aligning with demonstrable visual acuity improvements and the latter aligning with MN Read Scores.

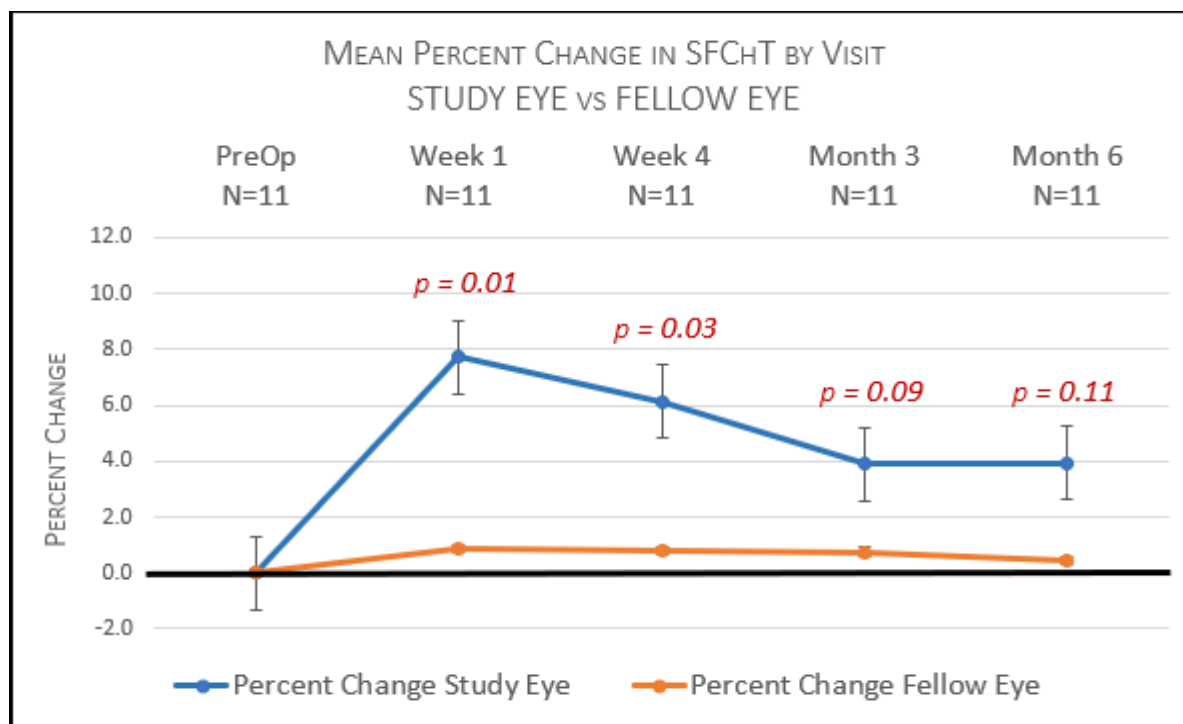
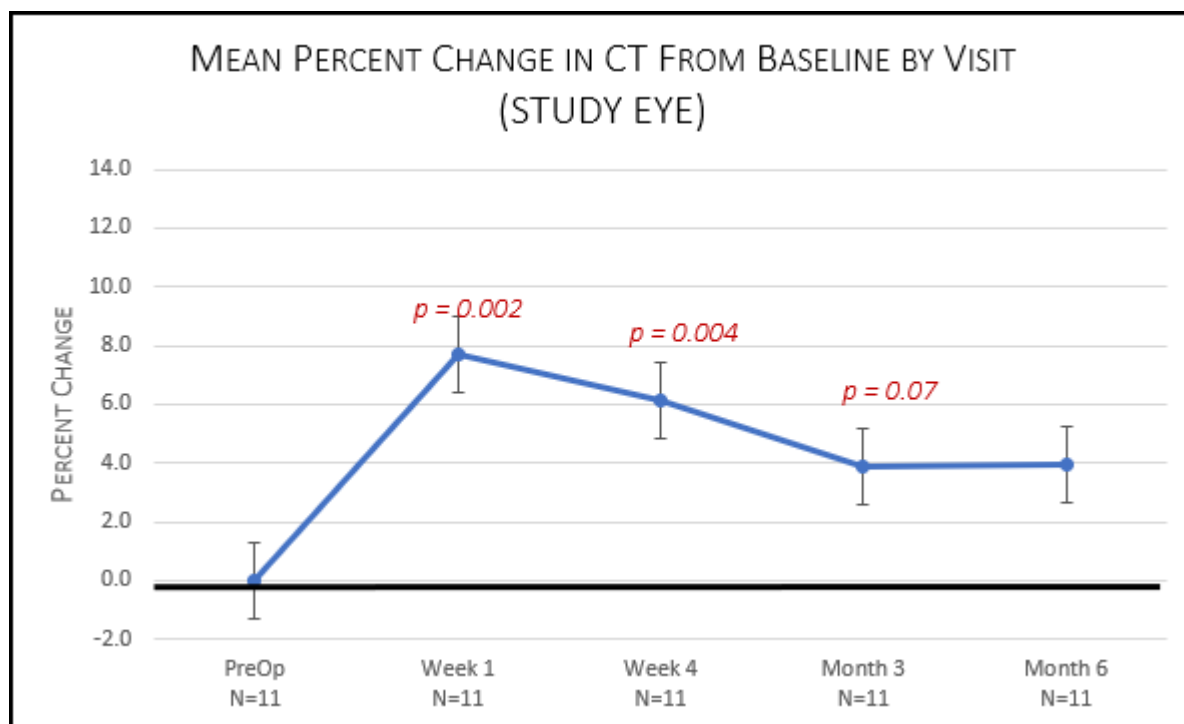
Objective Data

Sub-Foveal Choroidal Thickness (SFChT)



MEAN SUB-FOVEAL CHOROIDAL THICKNESS (SEM) BY VISIT

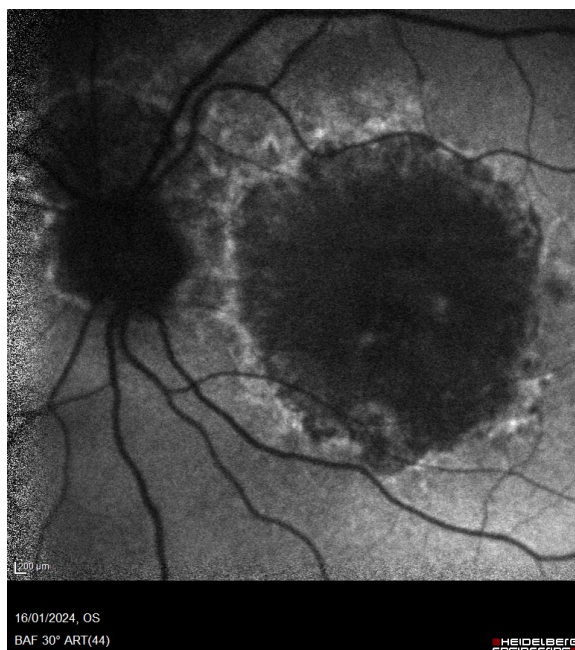
STUDY EYE OVER BASELINE AND COMPARED TO FELLOW EYE (N=11)



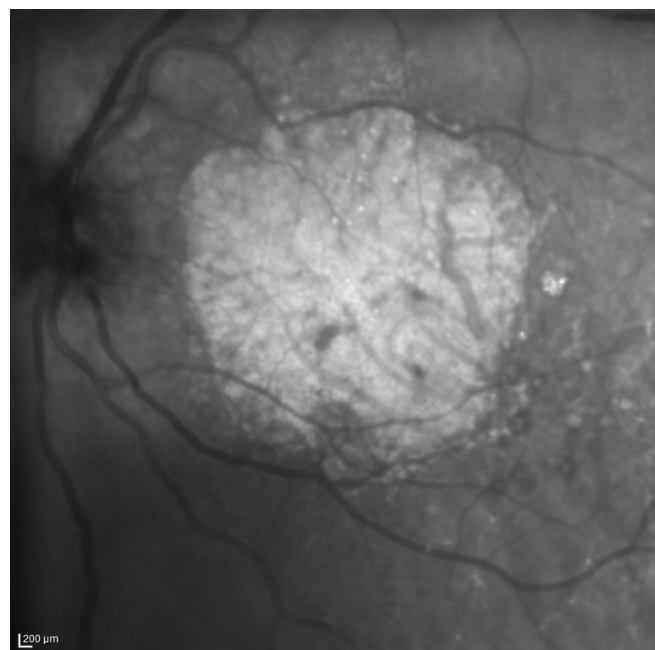
STATISTICAL SIGNIFICANCE OVER BASELINE AND FELLOW EYE TO WEEK 4, AS INCREASED PERFUSION RE-DISTRIBUTION TAKES PLACE

Geographic Atrophy (GA)

Autofluorescence



Infrared Reflectance



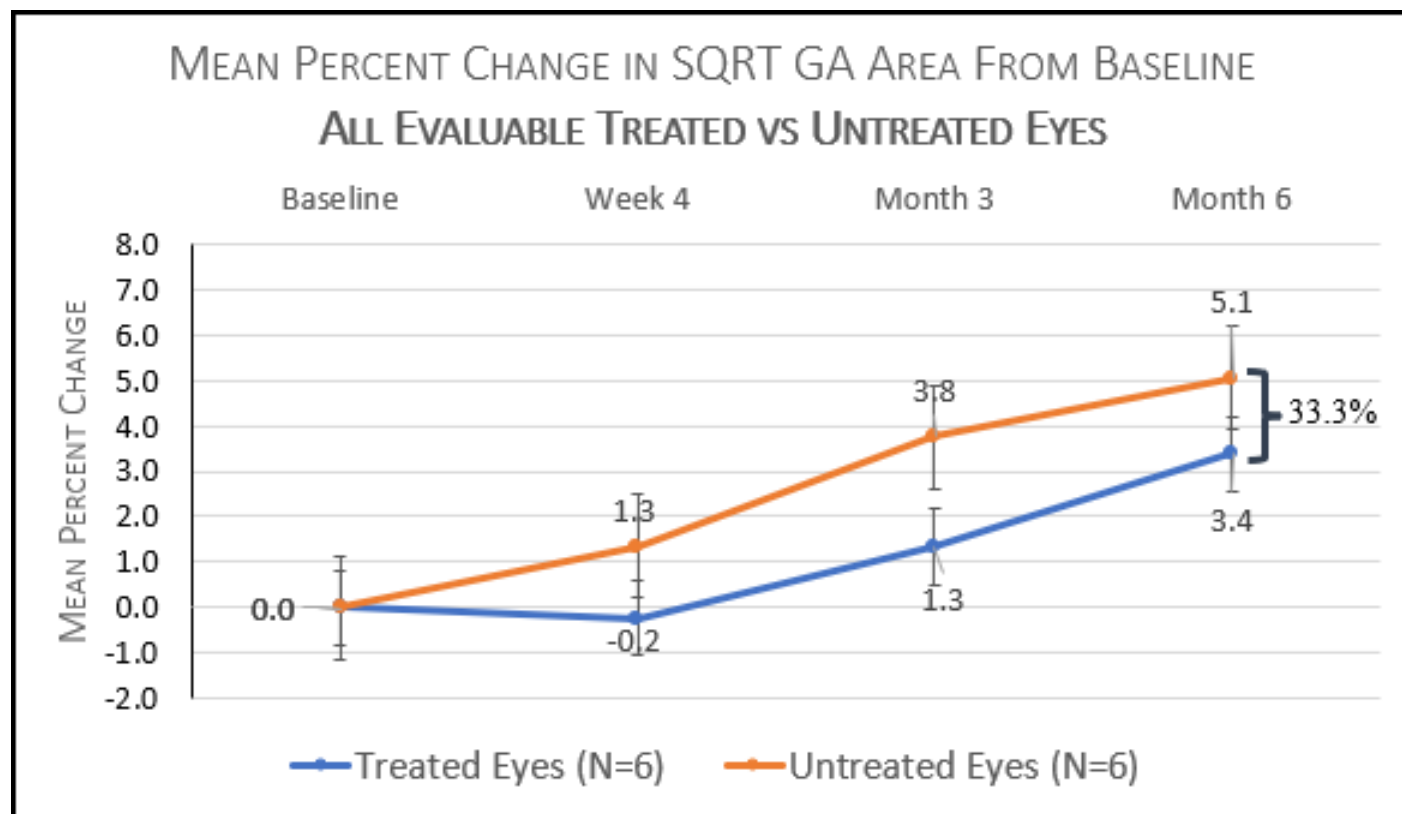
IMPORTANT TO NOTE:

- SUBJECTS WITH END-STAGE DISEASE, ADVANCED GA, AND PROFOUND VISION LOSS
- SMALL SAMPLE SIZE
 - 45.5% OF EACH COHORT (TREATED AND UNTREATED EYES) EVALUABLE
- EXCLUDED EYES
 - BEYOND FRAME (TOO LARGE)
 - PRIOR CNV / SCARRING
 - PERIPAPILLARY ATROPHY CONJOINED W/ GA
 - POOR IMAGE QUALITY
- NO STATISTICALLY SIGNIFICANT DIFFERENCES IN GA SQRT AREA BETWEEN COHORTS (P -VALUE: 0.08)*

* Two-tailed, paired t -test

GEOGRAPHIC ATROPHY BY VISIT (TREATED EYES VS UNTREATED EYES)

MEAN PERCENT CHANGE (SEM) THROUGH MONTH 6 VISIT
EVALUABLE COHORTS (N=6 EACH)



CASE STUDY

Subject 25-004

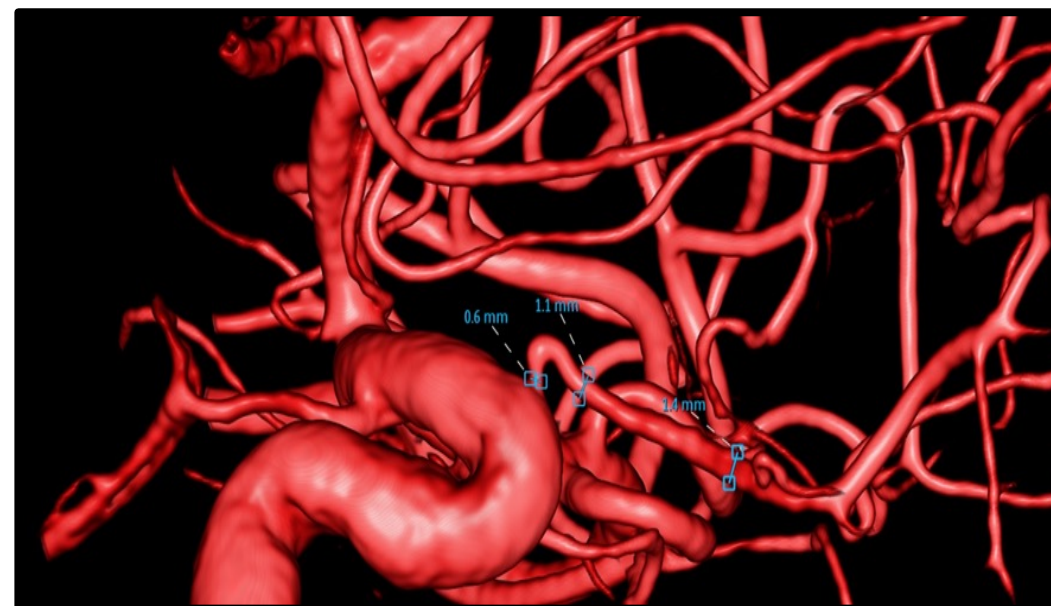
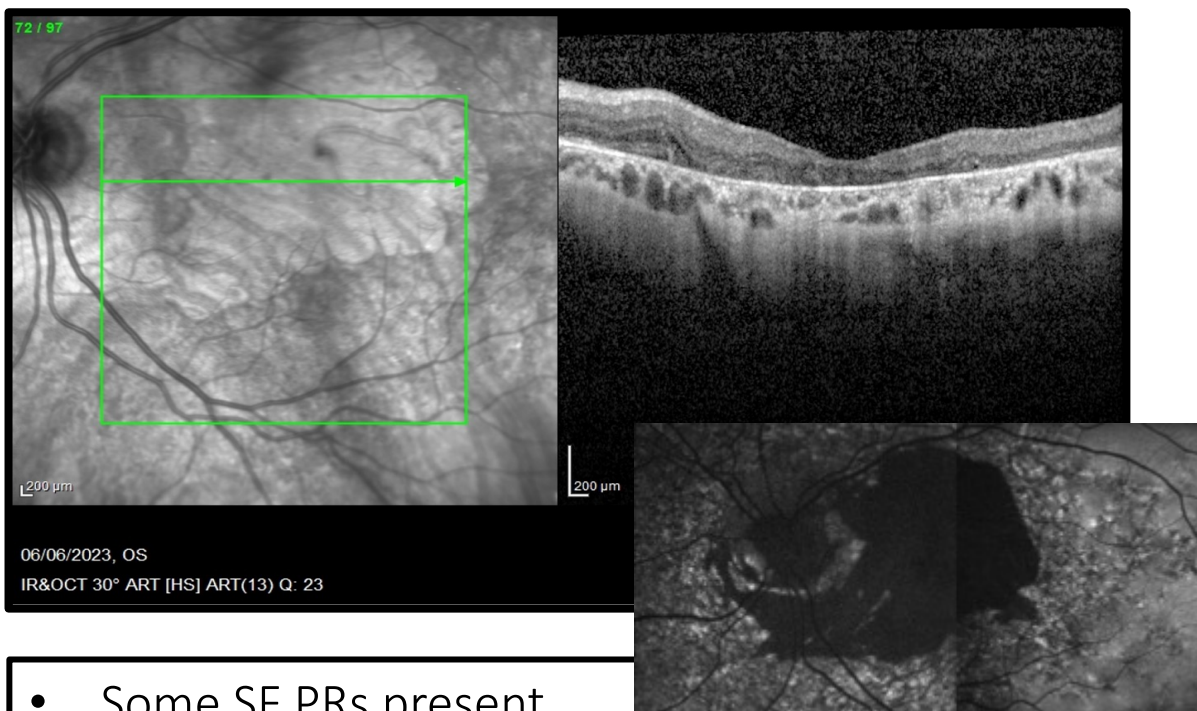
Demographics:

64yo Female with a BMI of 23.5, a positive familial history of AMD, and past history of smoking ~1/8 ppd X 1 year. Reported AMD diagnosis in 2014 with no remarkable vascular medical history.

Treatment Date:

11 July 2023

PROTOCOL OC-1901AR – SUBJECT 25-004 (OS)

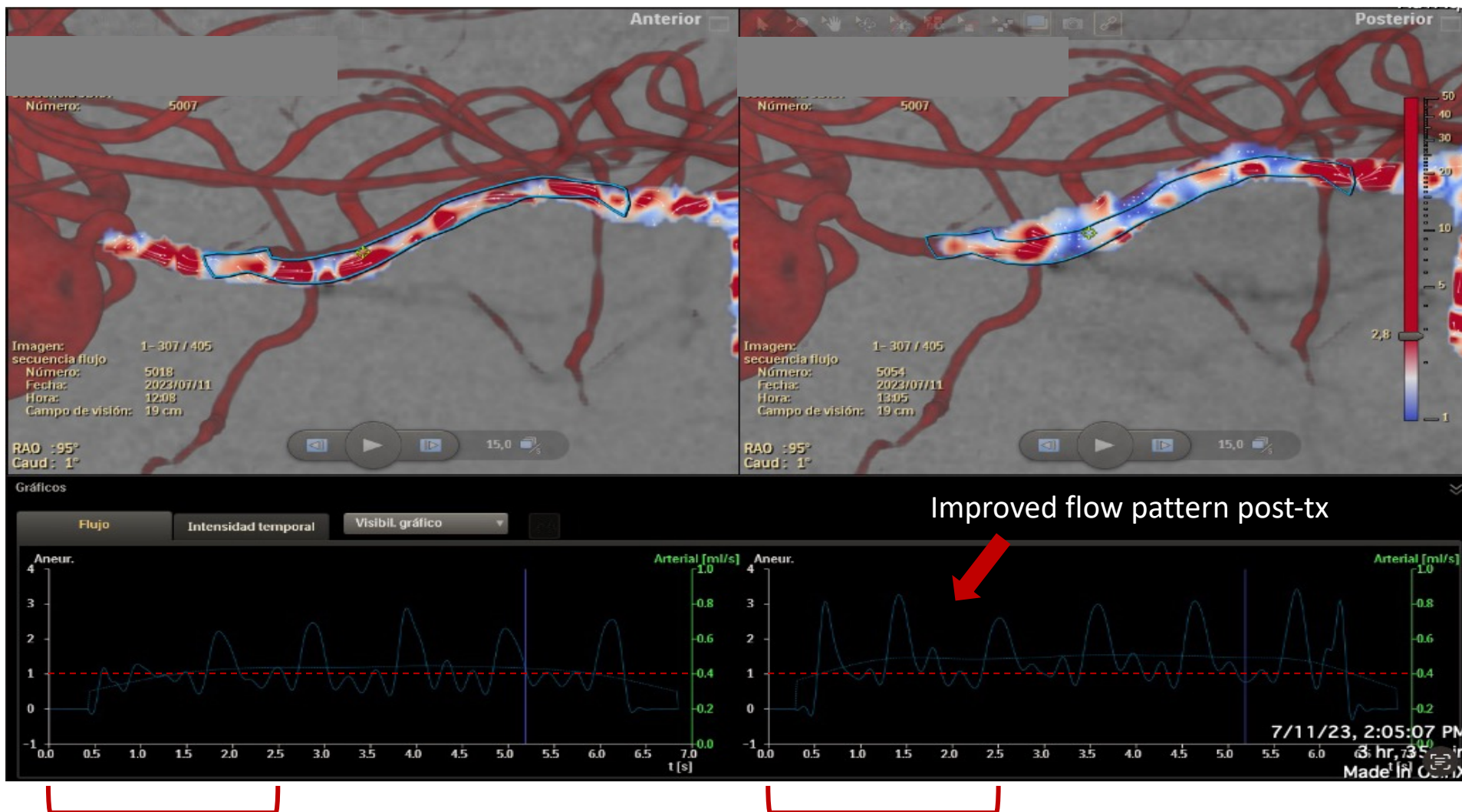


- Some SF PRs present
- Hyper transmission defect
- BM visible (loss of RPE)
- Dilated choroidal vessels
- GA, Hyper AF & RPD (FAF)

% Stenosis

57.9

MEAN ANEURISM FLOW AMPLITUDE (MAFA)*

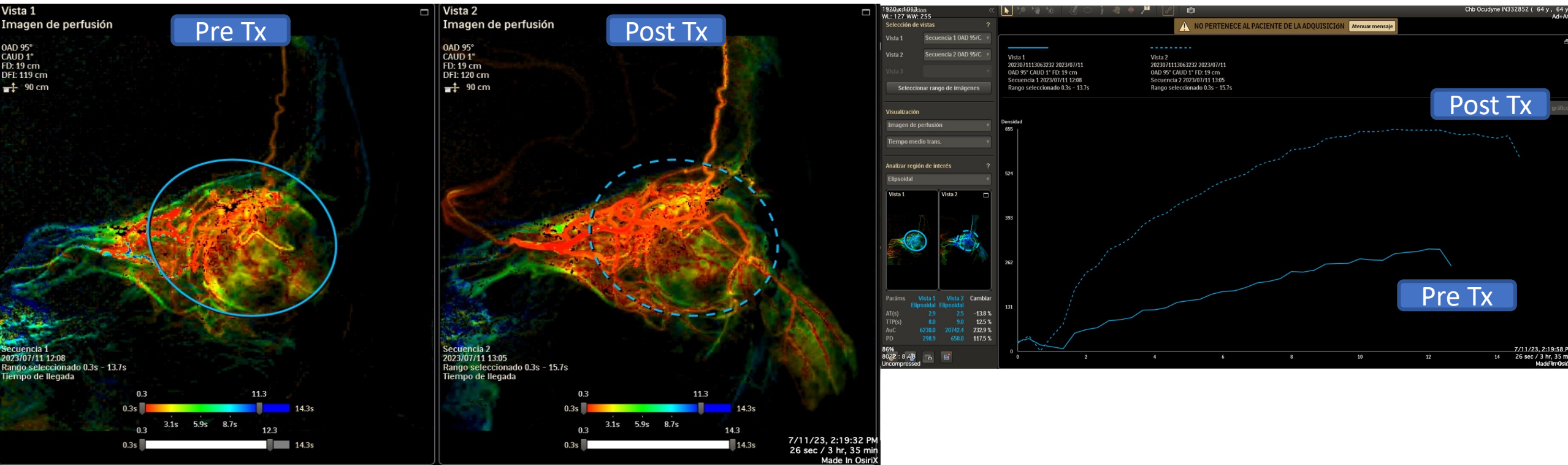


Elevated mean flow post-tx (+ ~30%)



*Adapted for Ophthalmic Artery Use

PHILIPS SMARTPERFUSION* – SUBJECT 25-004 (OS)

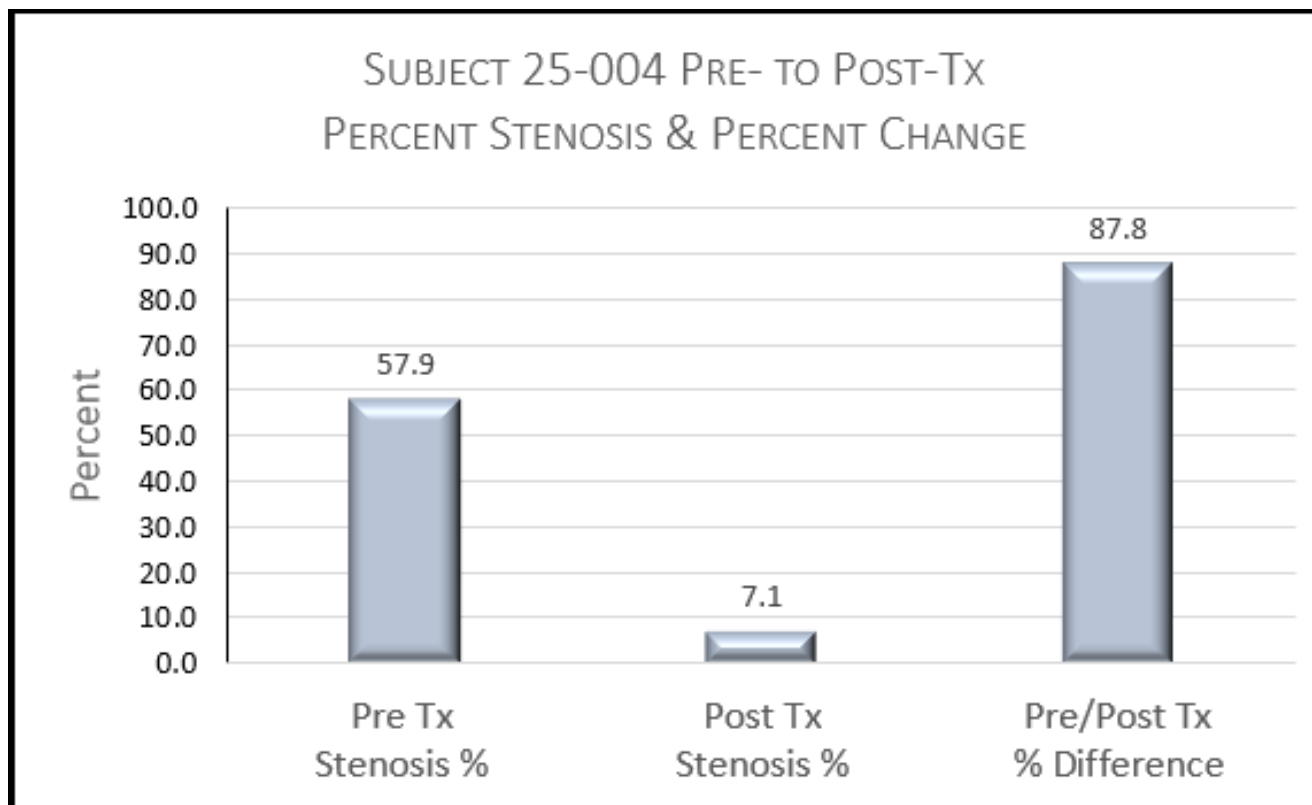


Paráms	Vista 1	Vista 2	Cambiar
	Elipsoidal	Elipsoidal	
AT(s)	2.9	2.5	-13.8 %
TTP(s)	8.0	9.0	12.5 %
AuC	6230.0	20742.4	232.9 %
PD	298.9	650.0	117.5 %

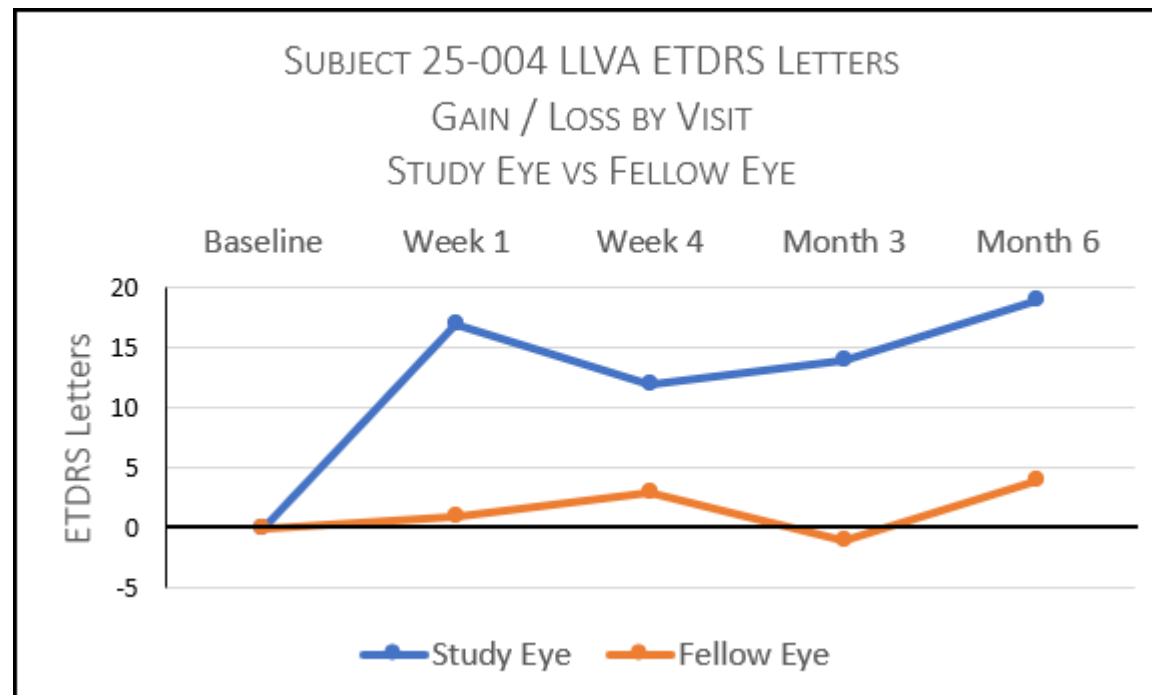
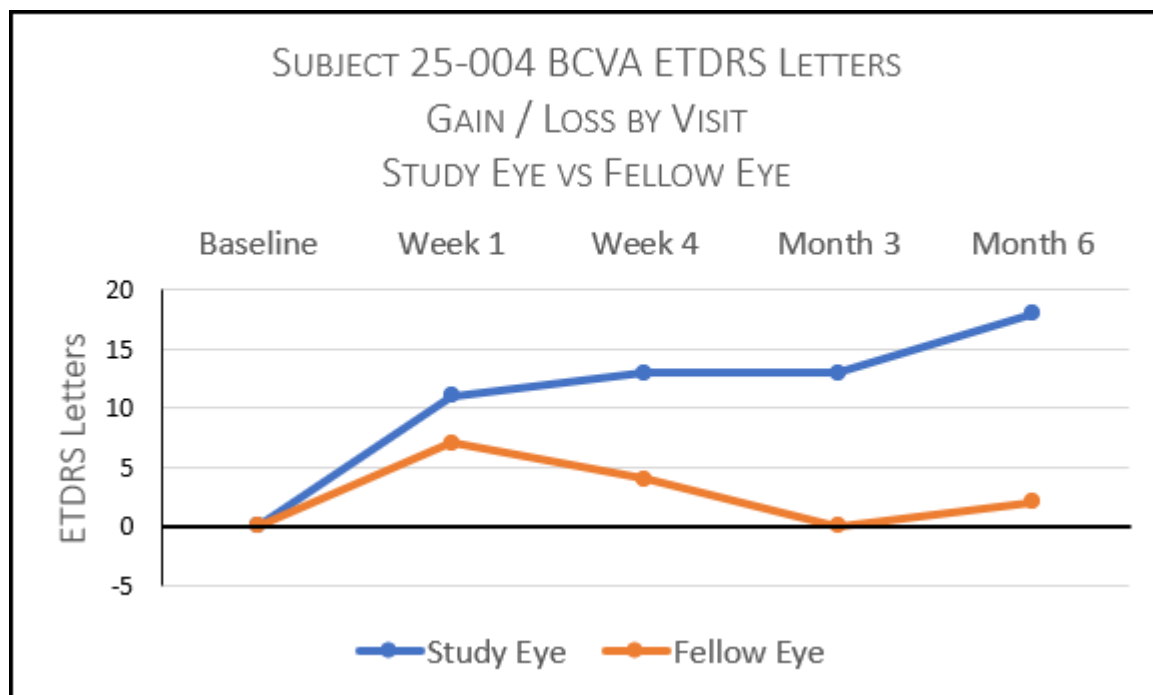
- Arrival Time (AT) decreased by 13.8%
- Time to Peak (TTP) increased by 12.5%
- Area under the Curve (AuC) increased by 232.9%
- Peak Density (PD) increased by 117.5%

*Adapted for Ophthalmic Artery Use

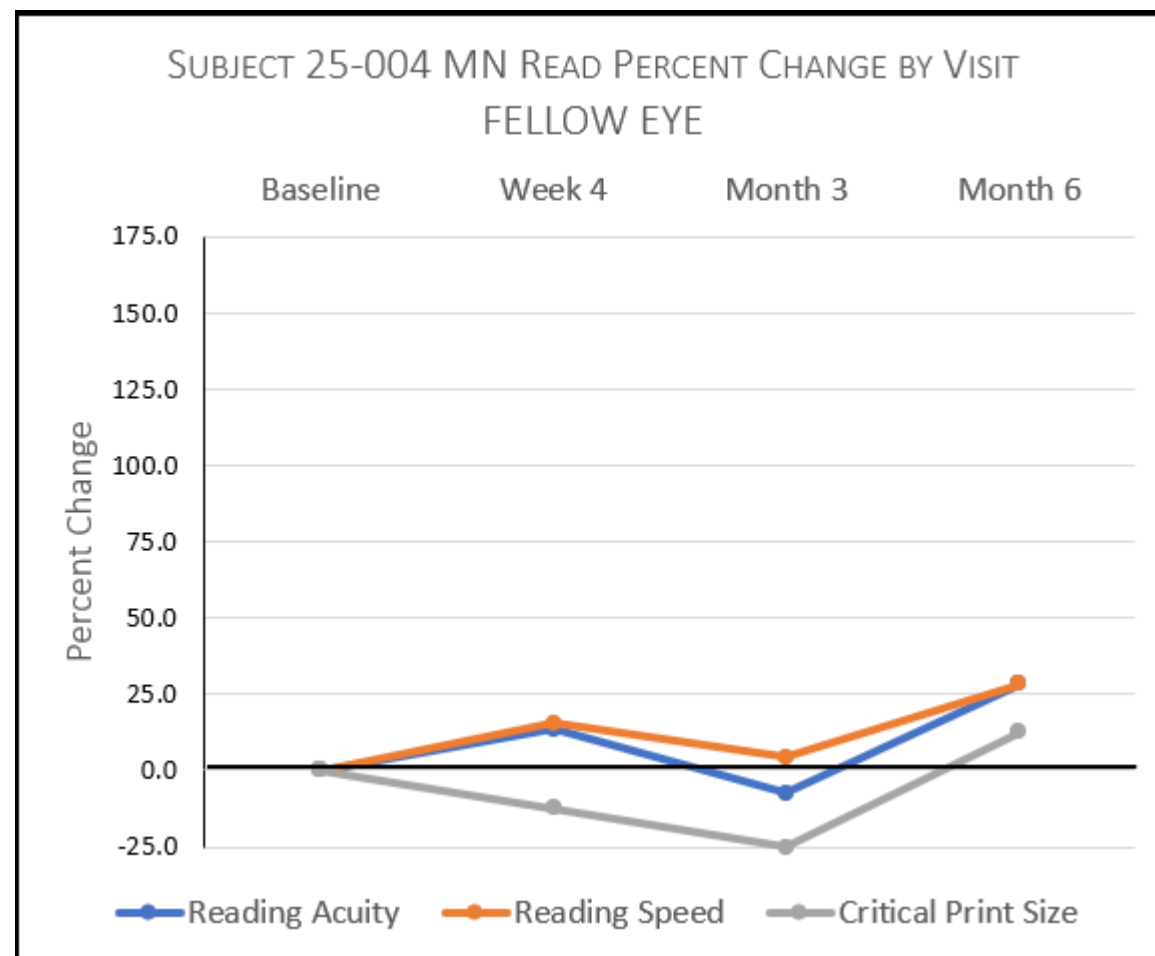
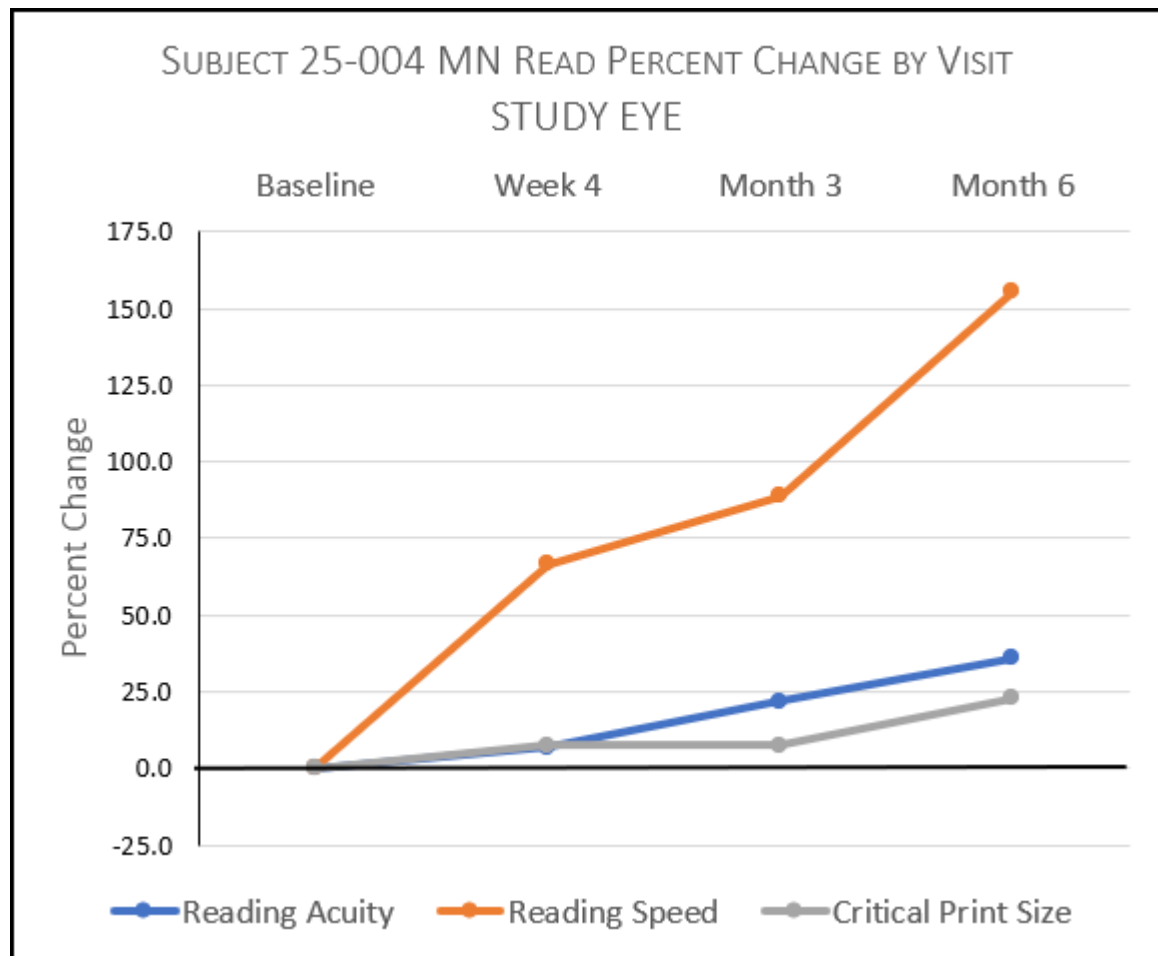
SUBJECT 25-004 (OS) - STENOSIS



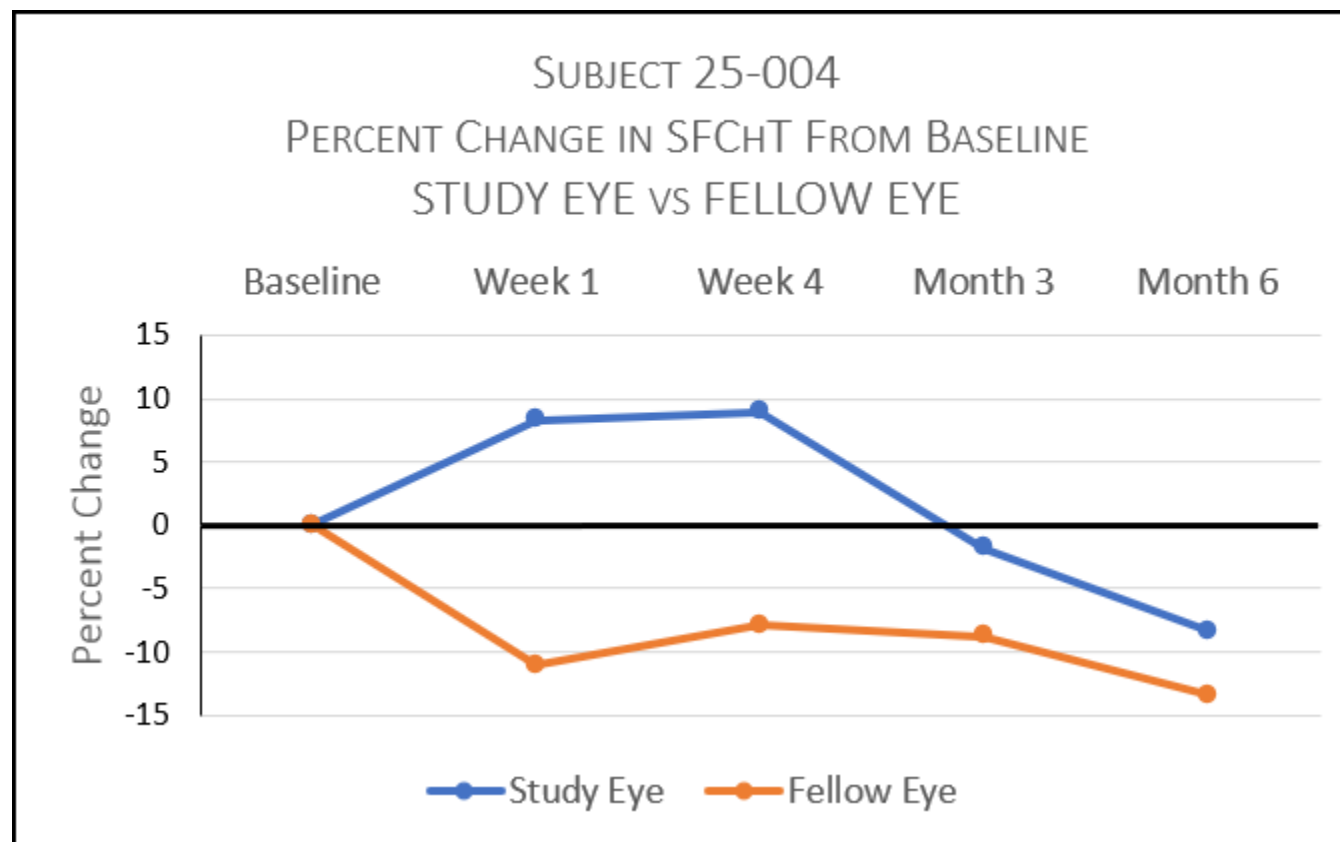
SUBJECT 25-004 (OS) – VISUAL ACUITY



SUBJECT 25-004 (OS) – MN READ



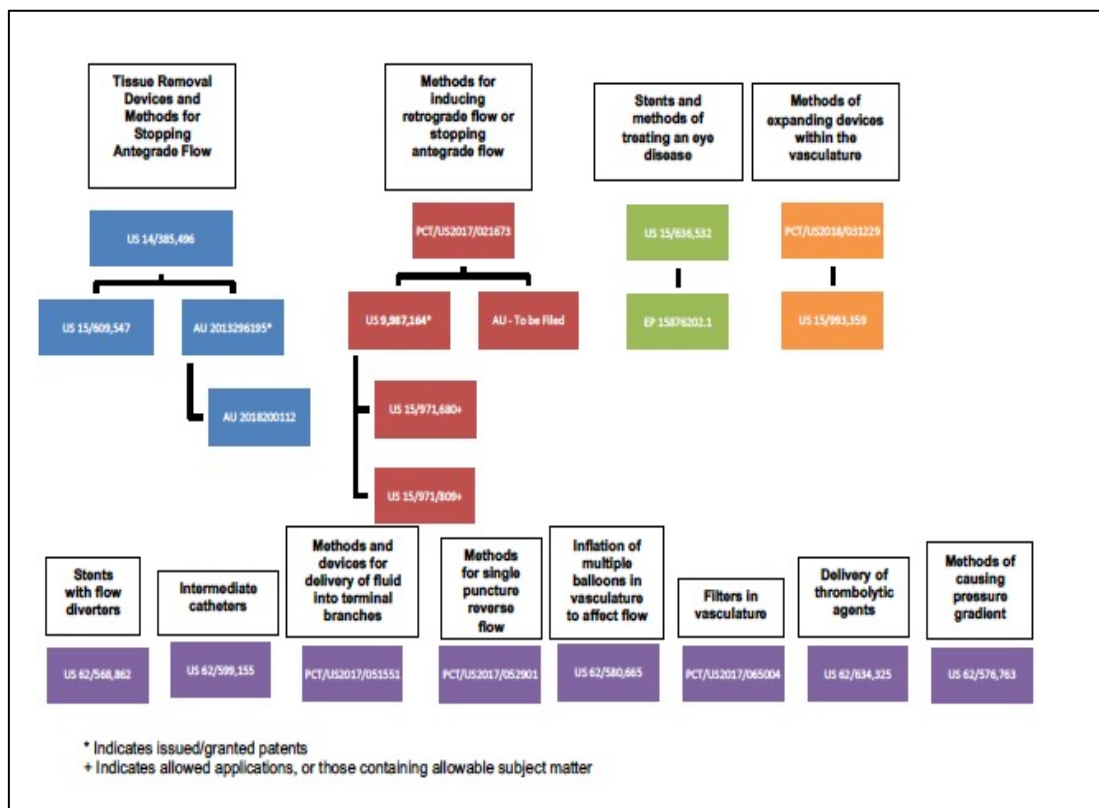
SUBJECT 25-004 (OS) – SFCHT



Intellectual Property

LARGE US AND INTERNATIONAL IP ESTATE

Over 40+ issued and pending patent applications



OCUDYNE CONFIDENTIAL INFORMATION

Ocudyne Patents and Pending Patent Applications (as of 10/03/18)

App. No. Pub. No. Filing Date* Priority Date	Ocudyne Ref. No. BoMc Ref. No.	Title	Status/Action Required/Due Dates
14/385,496 2017/0202574 09-15-2014 09-03-2012	OCU.04.US 00170-0002-01000	Devices and Methods for Treating Occlusion of the Ophthalmic Artery	Office Action mailed on June 22, 2018. We have received instructions to abandon this matter.
15/609,547 2017/0326001 06-31-2017 08-03-2012	OCU.04.US/CON 00170-0002-02000	Devices and Methods for Treating Occlusion of the Ophthalmic Artery	Amendment filed August 6, 2018. Awaiting next communication from USPTO.
2018200112 (to be inserted)	OCU.04.AU.Divisional 00170-0002-01110	Devices and Methods for Treating Occlusion of the Ophthalmic Artery	Request for Examination filed March 15, 2018.
01-05-201 08-03-2012	OCU.04.KR.Divisional 00170-0002-01202	Devices and Methods for Treating Occlusion of the Ophthalmic Artery	We have received instructions to abandon this matter.
KR 10-2017-1037090 (to be inserted)	OCU.04.KR.Divisional 00170-0002-01202	Devices and Methods for Treating Occlusion of the Ophthalmic Artery	We have received instructions to abandon this matter.
12-22-201708-03-2012 2013296195 AU2013296195	OCU.04.AU 00170-0002-00110	Devices and Methods for Treating Occlusion of the Ophthalmic Artery	Issued May 10, 2018.
08-06-2015 08-03-2012	OCU.04.KR 00170-0002-00202	Devices and Methods for Treating Occlusion of the Ophthalmic Artery	Issued December 22, 2017.
KR 10-2015-1813690 10-1813690	OCU.04.KR 00170-0002-00202	Devices and Methods for Treating Occlusion of the Ophthalmic Artery	Issued December 22, 2017.
12-22-2017 08-03-2012 15/636,532 2018/0140460	OCU.01.US 00170-0007-00000	Apparatus and Method for Treating Eye Diseases	Response to Missing Parts filed February 9, 2018. Awaiting next communication from USPTO.
06-28-2017 12-29-2014			

* All dates are in the following format: Month - Day - Year.

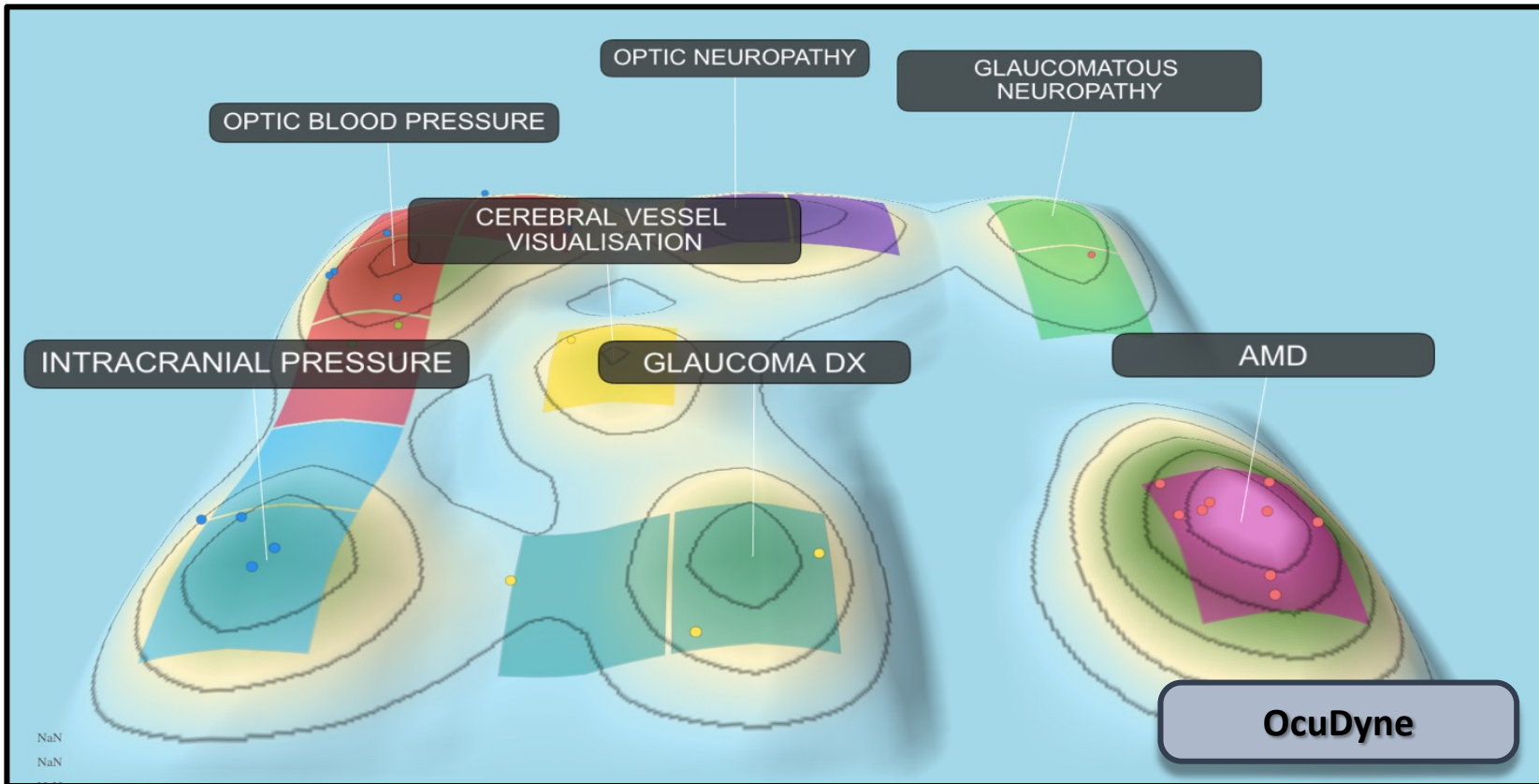
Page 1 of 4

App. No. Pub. No. Filing Date* Priority Date	Ocudyne Ref. No. BoMc Ref. No.	Title	Status/Action Required/Due Dates
PCT/US2017/051551 WO2018/051121 09-14-2017 09-15-2016	OCU16 and OCU20 00170-0006-00304	Systems and Methods for Treating an Eye Using Retrograde Blood Flow	National Stage due 03-15-2019.

Page 2 of 4

Page 3 of 4

IP LANDSCAPE – OCUDYNE EXCLUSIVE ISLAND



PatSnap
Landscape

Analysis:

Key word search in title / abstract for anatomic target (discovered by OcuDyne); by patent classification.